

*TESTING GALORE!!!*

*CASE DISCUSSION OF OCT RNFLS*

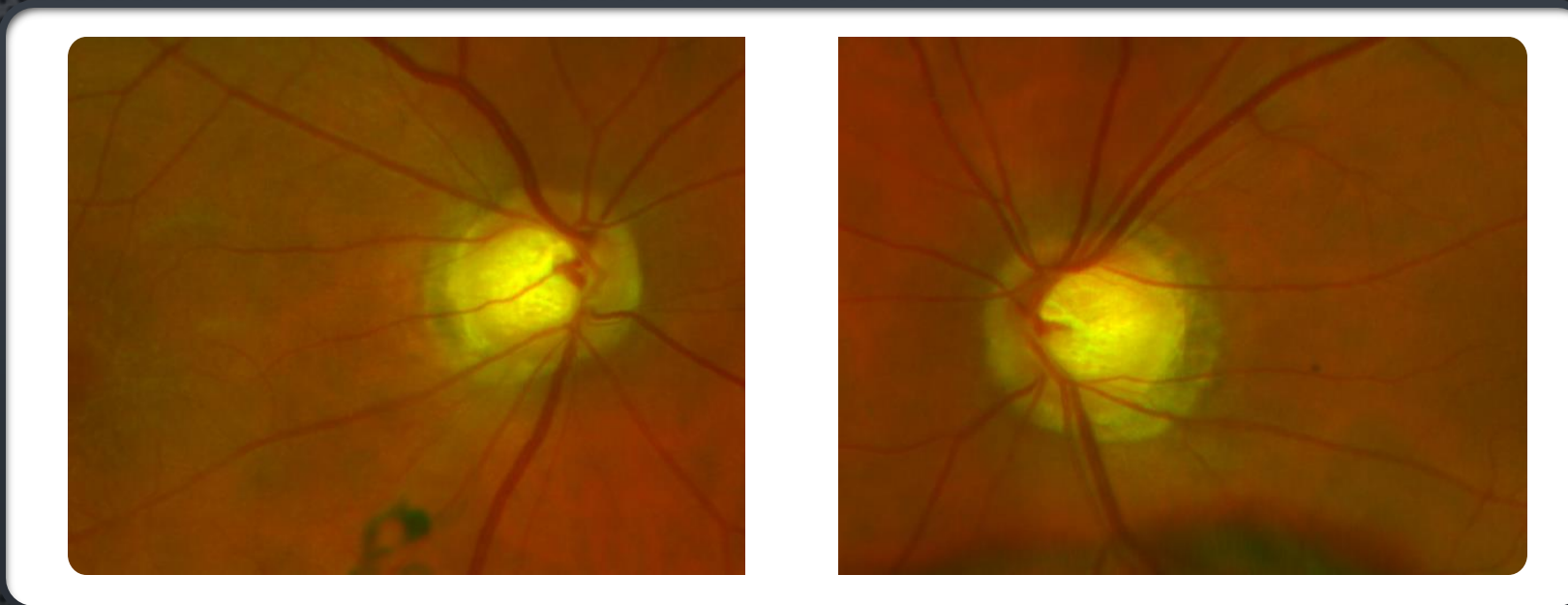
ISHA GUPTA, MD

UTAH EYE CENTERS

MARCH 4, 2023

# FINANCIAL DISCLOSURES

ISHA GUPTA, MD (INSTRUCTOR): NO FINANCIAL INTEREST TO DISCLOSE



GLAUCOMA OR NOT?

# OCT RNFL

- DETERMINES THICKNESS OF RETINAL NERVE FIBERS AS THEY EMANATE FROM OPTIC NERVE
- COMPARES THICKNESS TO NORMATIVE DATABASE OF AGE-MATCHED CONTROLS
- ANY OPTIC ATROPHY WILL BE REVEALED IN RNFL
- SUBJECT TO MULTIPLE ARTIFACTS
- QUALITY AFFECTED BY MEDIA OPACITY E.G. CORNEA, CATARACT ETC

# OCT RNFL: IMAGE ACQUISITION

## **TIME DOMAIN: (ZEISS STRATUS)**

400 AXIAL SCANS/SECOND

7-8 MM AXIAL RESOLUTION

MOTION ARTIFACTS/CENTRATION DIFFICULT

## **SPECTRAL DOMAIN (ZEISS SPECTRAL DOMAIN)**

6X6 MM<sup>2</sup> CUBE OVER ONH

27,000 AXIAL SCANS/SECOND WITH B SCANS IN SAME LOCATION

5 MICRON AXIAL RESOLUTION

C/D DIMENSIONS, VERT/HORIZONTAL C/D, DISC AREA, CUP VOLUME ETC

## **SPECTRAL DOMAIN (HEIDELBERG SPECTRALIS)**

40,000 AXIAL SCANS/SECOND WITH 6 CONSECUTIVE CIRCULAR B-SCANS

3.9 MICRON AXIAL RESOLUTION

# OCT RNFL: NORMATIVE DATABASE

Slightly different for each company

Cirrus: 284 subjects, 47% male, 53% female

Age: 18-84

Rx: -12D to + 8D

43% Caucasian, 18% African American, 12%  
Hispanic, 1% Indian, 6% mixed

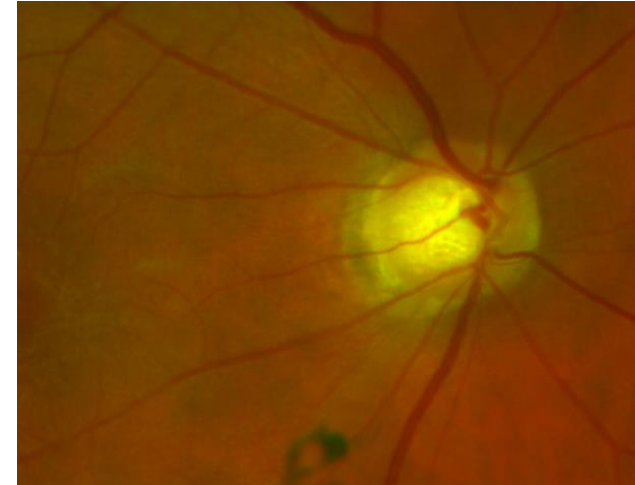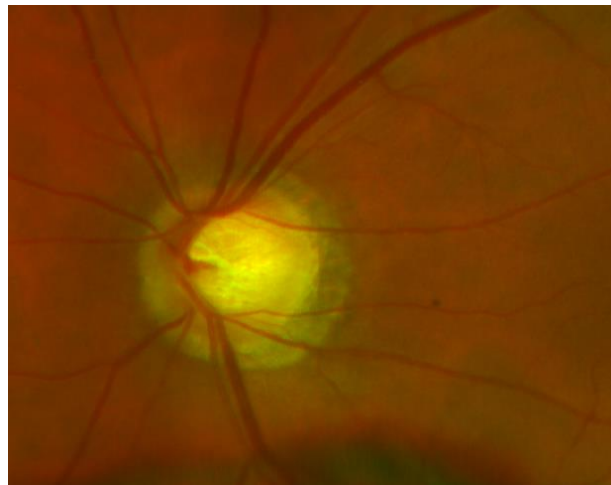
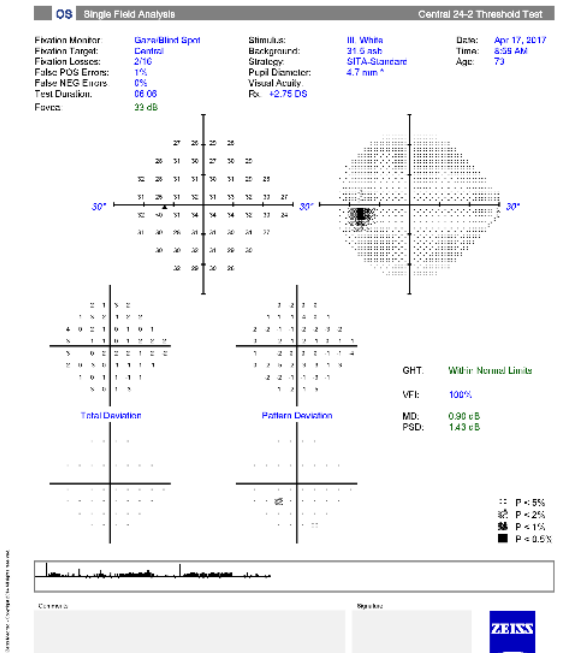
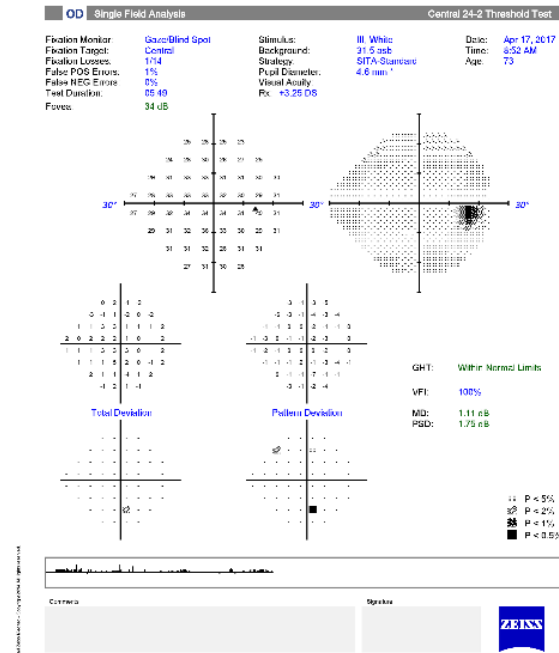
All normal subjects

# OCT RNFL: WHEN?

- PATIENT CANNOT PERFORM VISUAL FIELD
- WHEN VISUAL FIELD IS INCONCLUSIVE OR TO SUPPORT VF FINDINGS
- NO VISUAL FIELD LOSS IS NOTED ON A VF BUT HIGH SUSPICION OF OPTIC NERVE DAMAGE (I.E. PRE-PERIMETRIC OPTIC NERVE DAMAGE)
- IN ADDITION TO VISUAL FIELD – STAGGERING VISUAL FIELDS AND RNFLs PROVIDE ADDITIONAL SURVEILLANCE OF FUNCTIONAL/STRUCTURAL LOSS
- TO RULE OUT OPTIC ATROPHY WHEN NERVE LOOKS SUSPICIOUS (PALLOR>CUPPING)
- MOST OCT RETINA SYSTEMS CAN DO OCT RNFL

# CASE 1

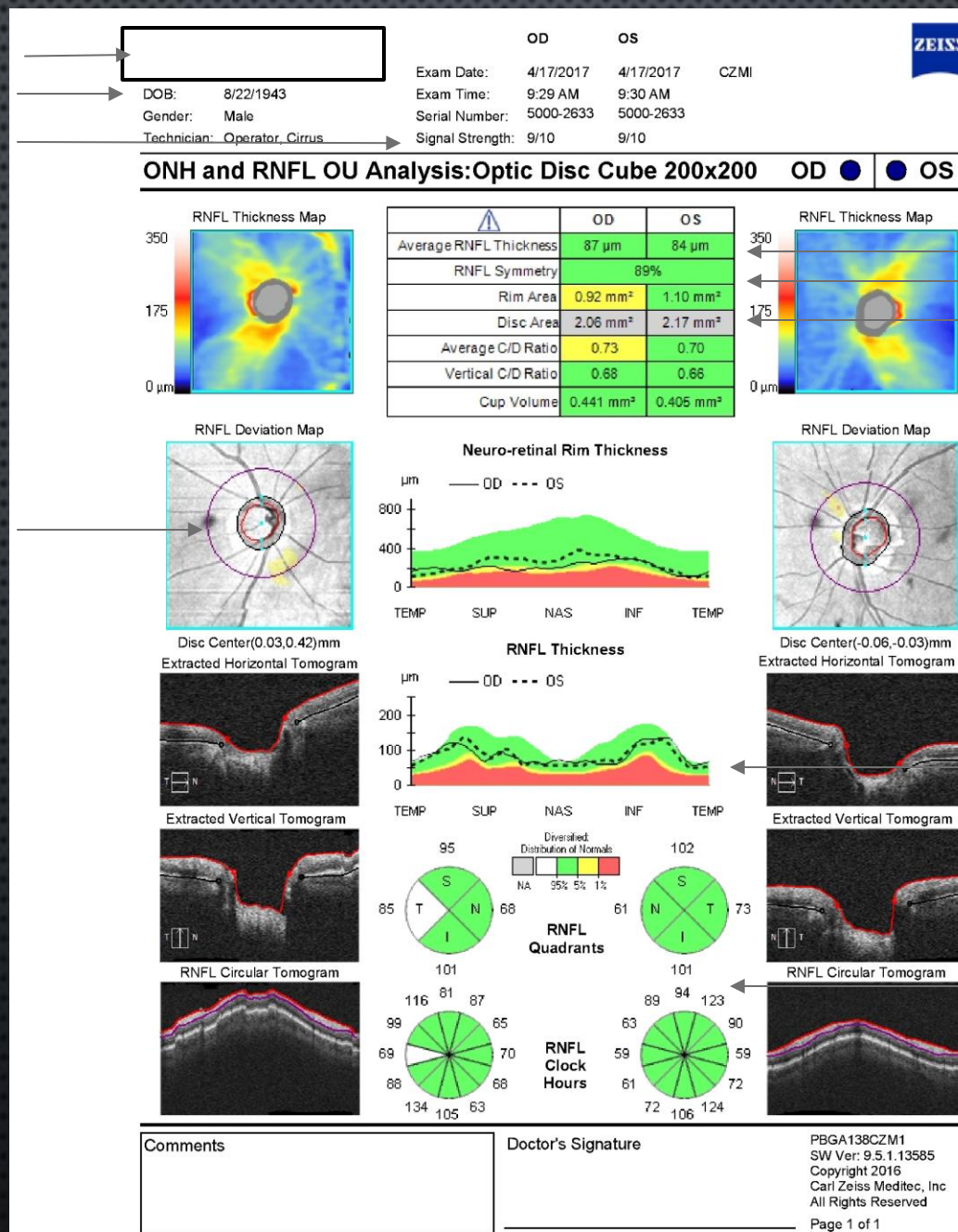
- PATIENT REFERRED FOR GLAUCOMA EVALUATION FOR LARGE C/D RATIO OU
- 73 YO MALE, NO FH, CCT: 572/590, IOP 14 OU, CE/IOL OU, GRADE 4 ANGLE OU
- C/D: 0.7 OU, ERM OD WITH FULL FIELDS



Correct patient  
Correct DOB  
Adequate signal strength

Image captured  
correctly

Quality Assessment



Avg RNFL thickness  
Symmetry  
Disk Area

**Green:** 95% population with that level  
**White:** above average  
**Yellow:** borderline < 5% population  
**Red:** Significant < 1% population

Distribution of OD and OS RNFL  
Thickness and comparison with  
normative database

Localization of thickness  
(quadrants & clock hours)

Data Interpretation

# CASE 1: ASSESSMENT AND PLAN

Physiologic cupping

No additional risk factors

F/U 1 year with DFE and consider RNFL

Small disc  $< 1.65 \text{ mm}^2$

Average disc  $1.65\text{-}2.00 \text{ mm}^2$

Large disc  $> 2.00 \text{ mm}^2$

## CASE 2

- 82 YO MALE DIAGNOSED WITH GLAUCOMA 6 YEARS PRIOR
- TMAX – TEENS, NO FH, NO VASCULOPATHIC RISK FACTORS
- CCT 559/551, OPEN ON GONIO
- NO SURGERIES/LASERS/MED ALLERGIES/INTOLERANCE
- ON COMBIGAN BID OD AND TIMOLOL QAM OS

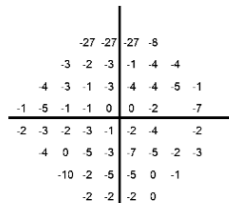
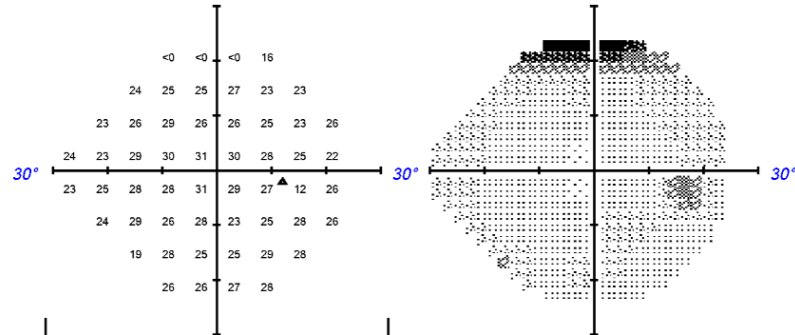
# OD Single Field Analysis

## Central 24-2 Threshold Test

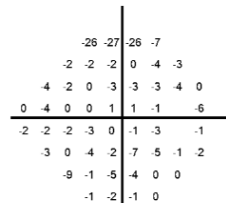
Fixation Monitor: Gaze/Blind Spot  
 Fixation Target: Central  
 Fixation Losses: 2/16  
 False POS Errors: 6%  
 False NEG Errors: 0%  
 Test Duration: 05:32  
 Fovea: 33 dB

Stimulus: III, White  
 Background: 31.5 asb  
 Strategy: SITA-Standard  
 Pupil Diameter: 3.1 mm \*  
 Visual Acuity: Rx: +5.50 DS

Date: Dec 23, 2016  
 Time: 8:42 AM  
 Age: 81




Total Deviation



Pattern Deviation

GHT: Outside Normal Limits  
 VFI: 94%  
 MD: -3.57 dB P < 1%  
 PSD: 4.98 dB P < 0.5%

:: P < 5%  
 ☒ P < 2%  
 ☒ P < 1%  
 ■ P < 0.5%



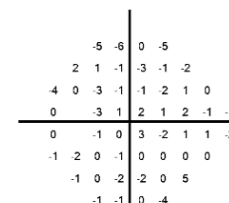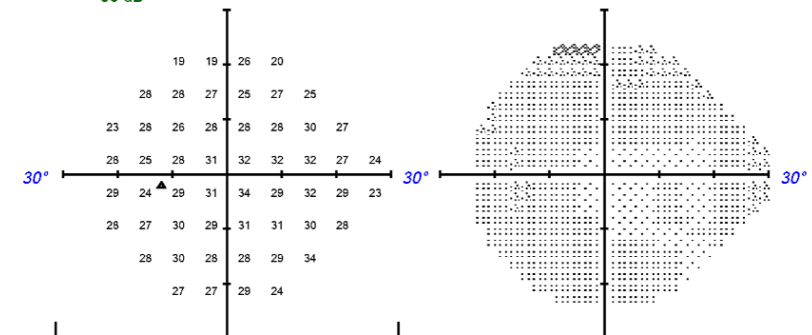
# OS Single Field Analysis

## Central 24-2 Threshold Test

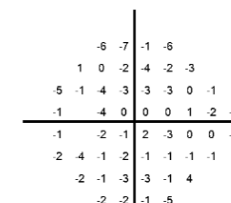
Fixation Monitor: Gaze/Blind Spot  
 Fixation Target: Central  
 Fixation Losses: 2/15  
 False POS Errors: 7%  
 False NEG Errors: 5%  
 Test Duration: 05:19  
 Fovea: 36 dB

Stimulus: III, White  
 Background: 31.5 asb  
 Strategy: SITA-Standard  
 Pupil Diameter: 3.1 mm \*  
 Visual Acuity: Rx: +5.50 DS

Date: Dec 23, 2016  
 Time: 8:49 AM  
 Age: 81




Total Deviation

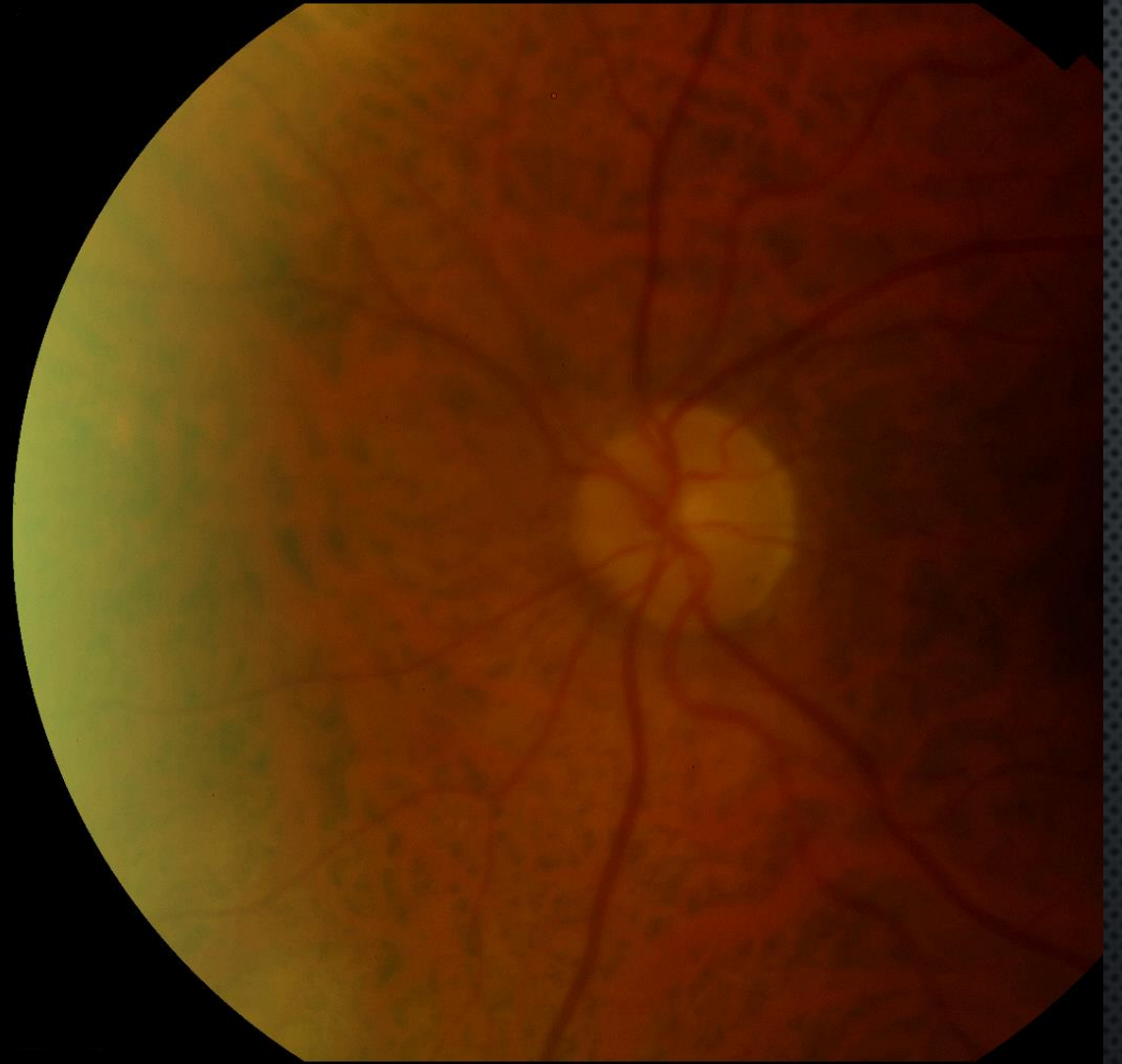
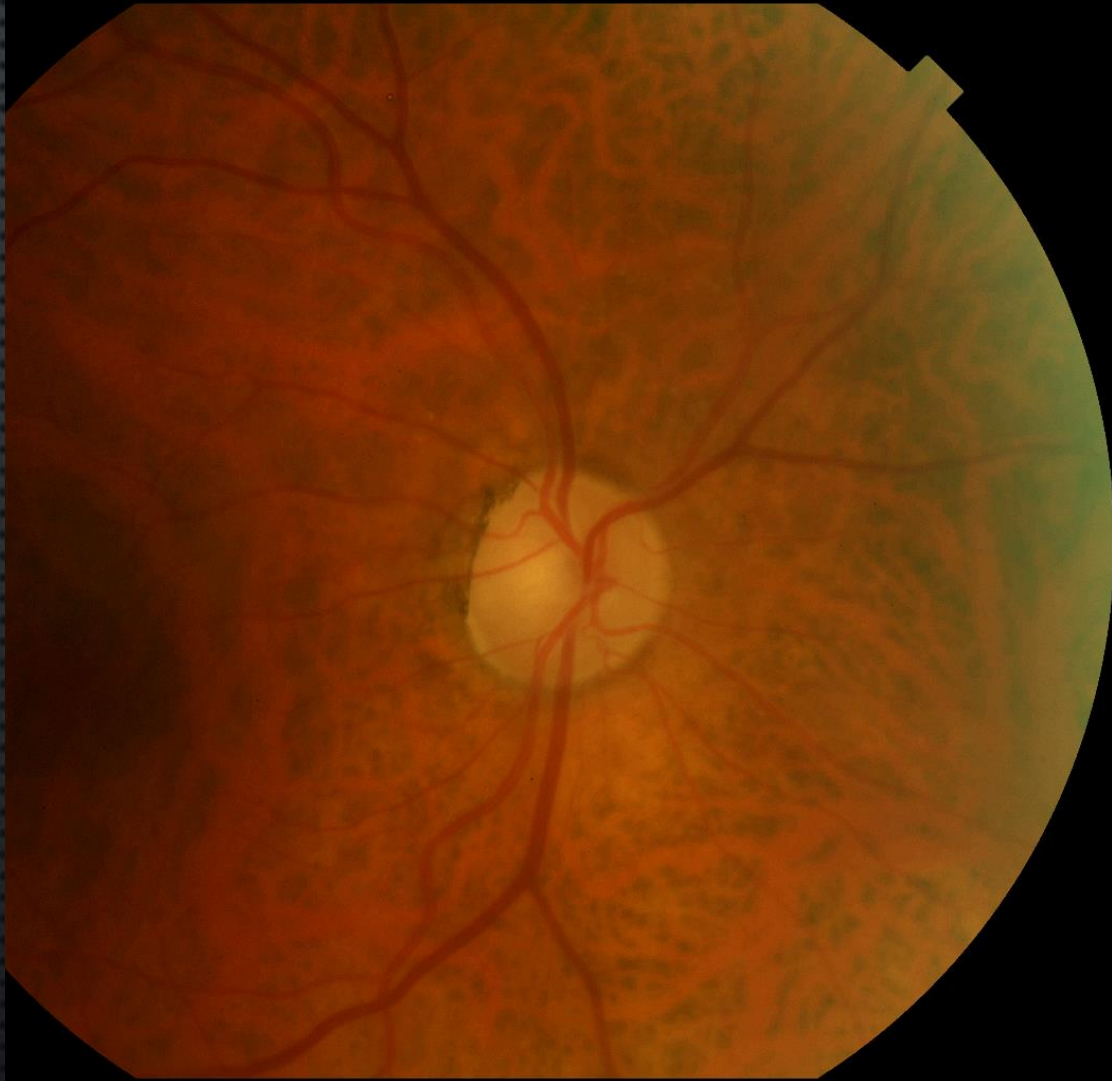


Pattern Deviation

GHT: Within Normal Limits  
 VFI: 99%  
 MD: -0.48 dB  
 PSD: 1.97 dB P < 10%

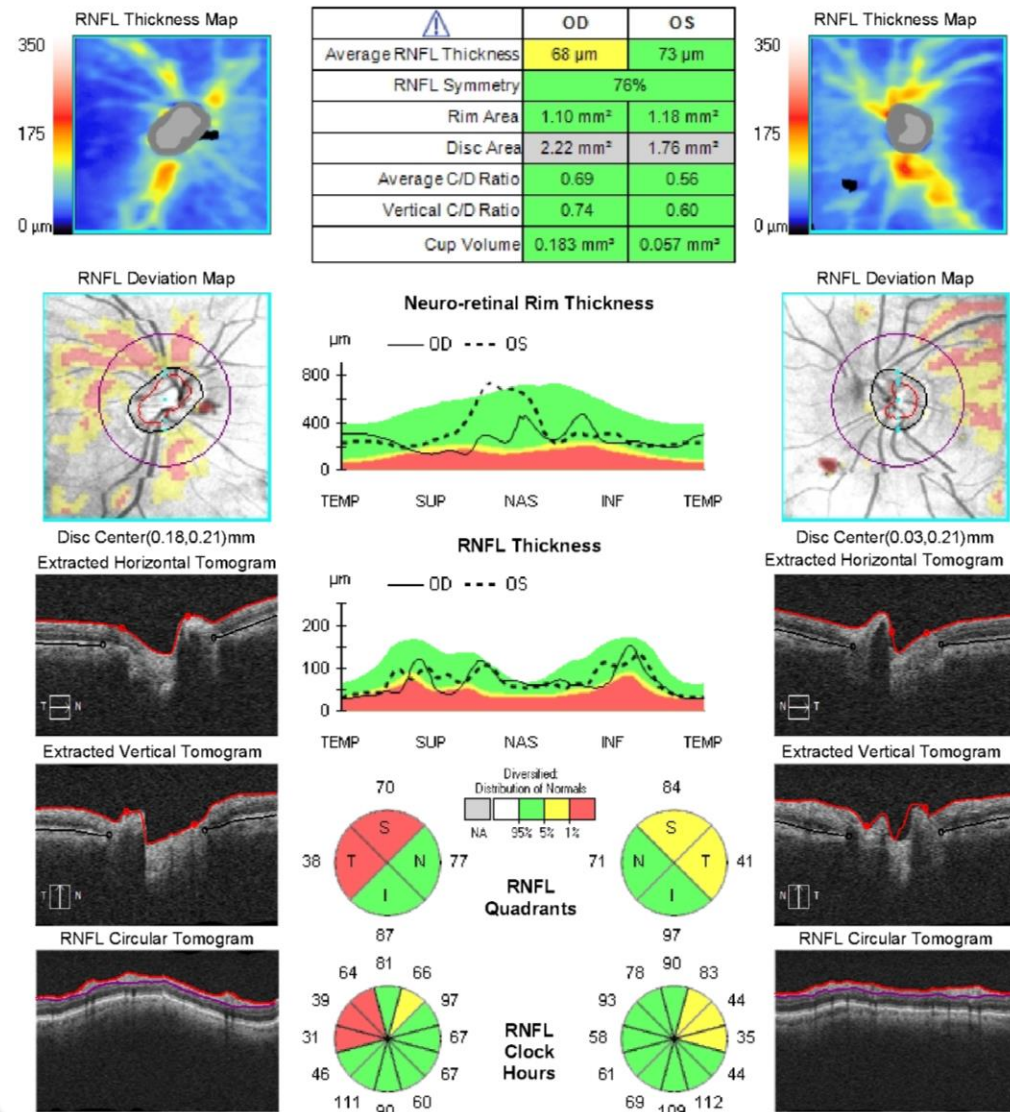
:: P < 5%  
 ☒ P < 2%  
 ☒ P < 1%  
 ■ P < 0.5%





DOB: 5/18/1935 Exam Time: 8:25 AM 8:27 AM  
 Gender: Male Serial Number: 5000-2633 5000-2633  
 Technician: Operator, Cirrus Signal Strength: 9/10 8/10

# ONH and RNFL OU Analysis: Optic Disc Cube 200x200 OD OS



## CASE 2

- CORRECT AGE, MALE
- RELIABLE, GOOD SIGNAL STRENGTH
- VERY MINOR ARTIFACTS
- FINDINGS: LARGE DISK, TILTED
- OD: SUPERIOR AND TEMPORAL THINNING
- OS: BORDERLINE SUPERIOR/TEMPORAL THINNING

# CASE 2: ASSESSMENT AND PLAN

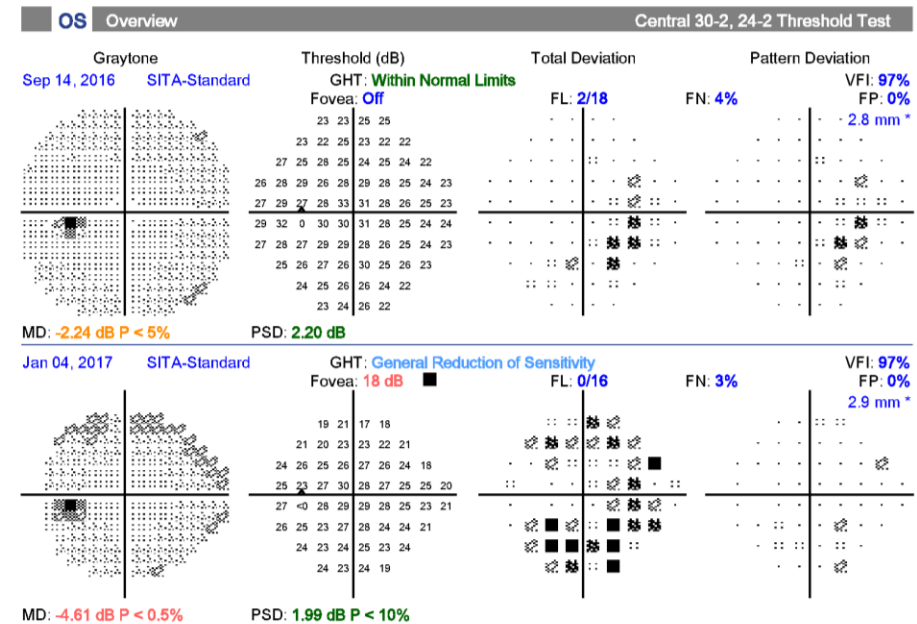
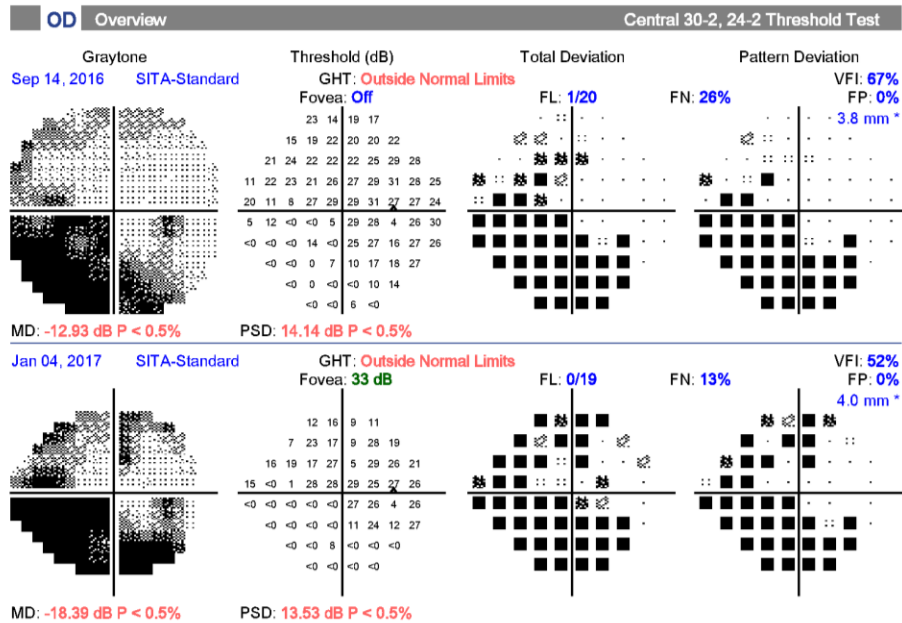
POAG-MILD OD, SUSPECT OS

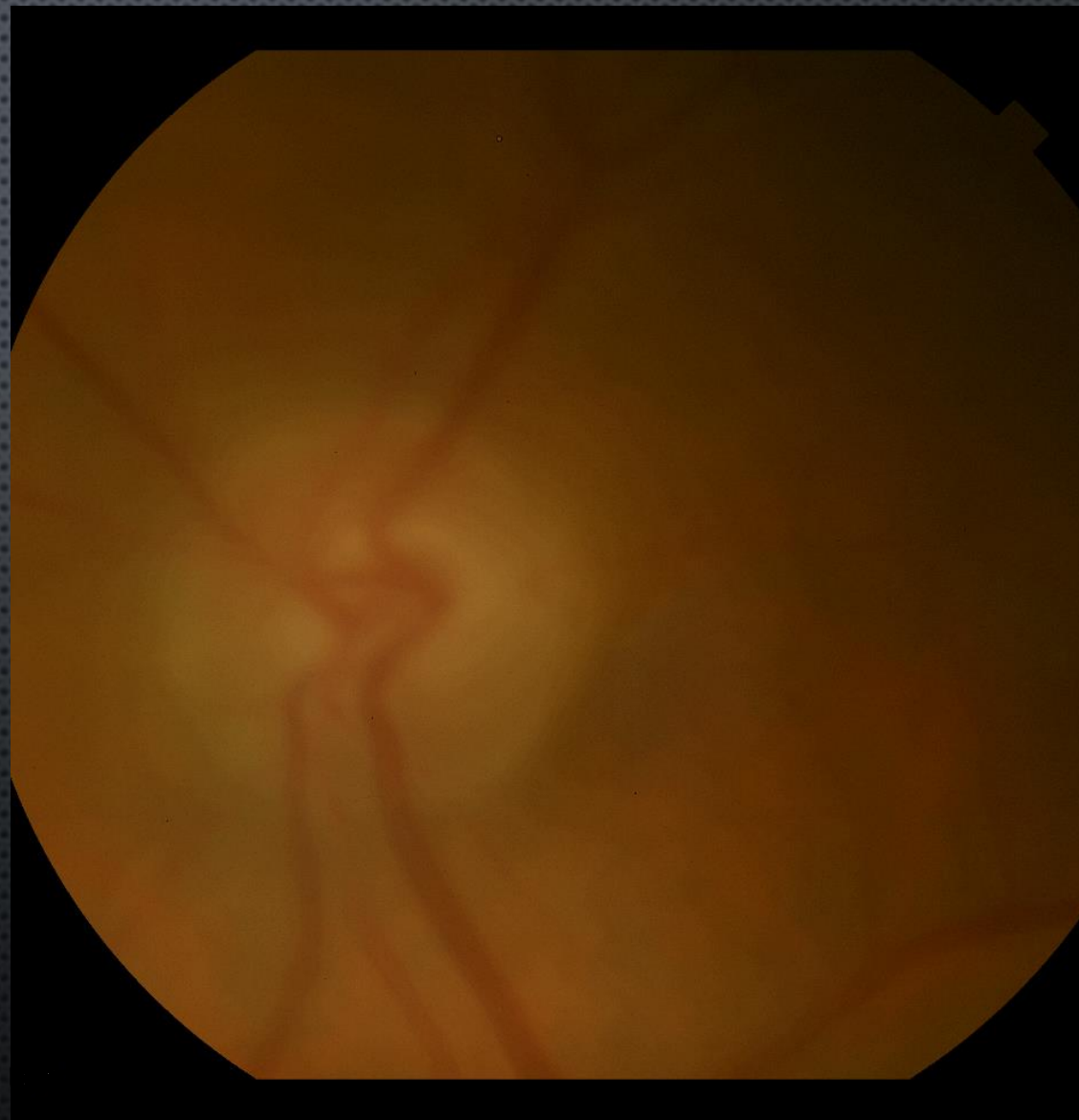
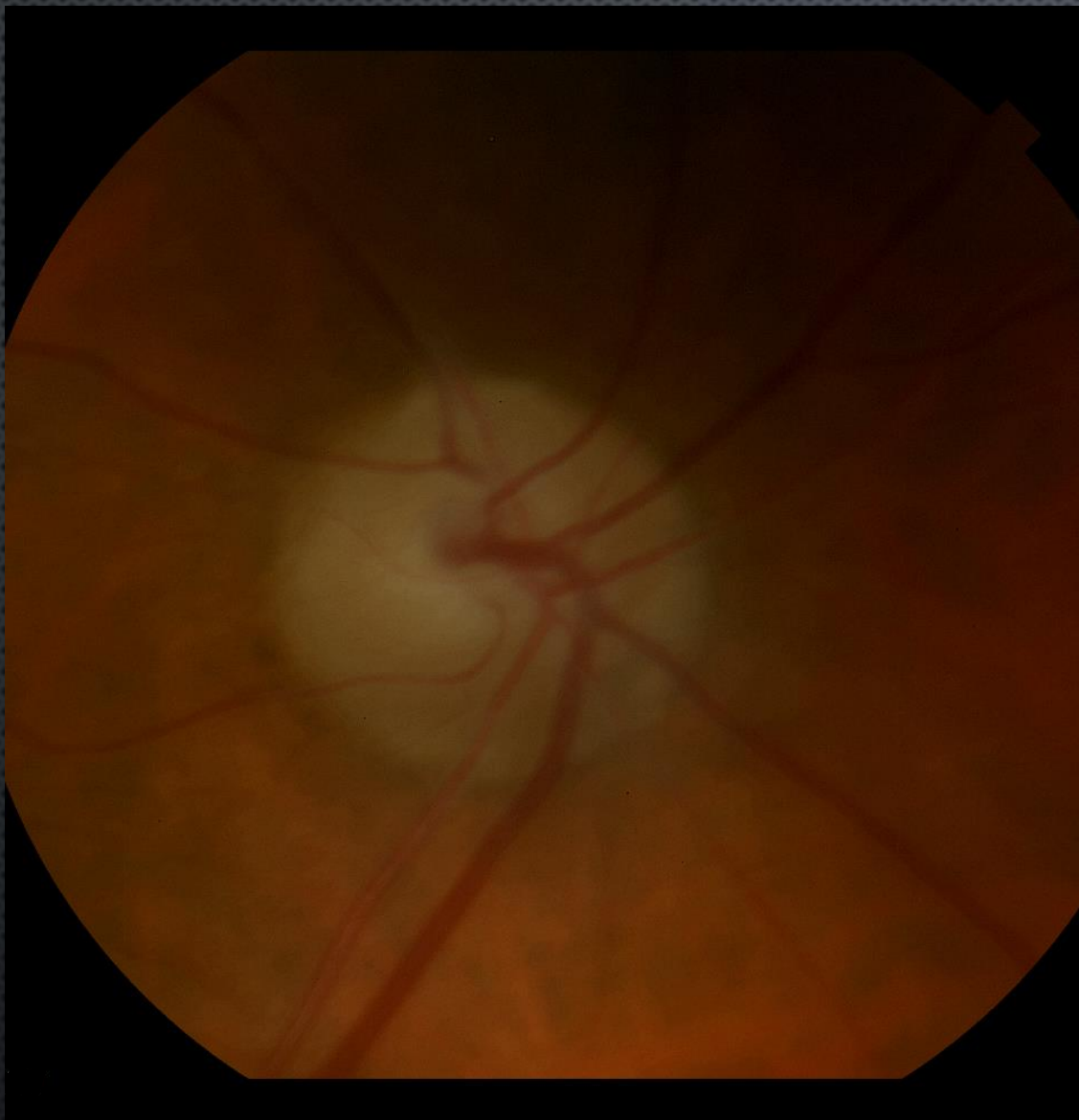GLAUCOMA THERAPY (MEDS VS LASER)

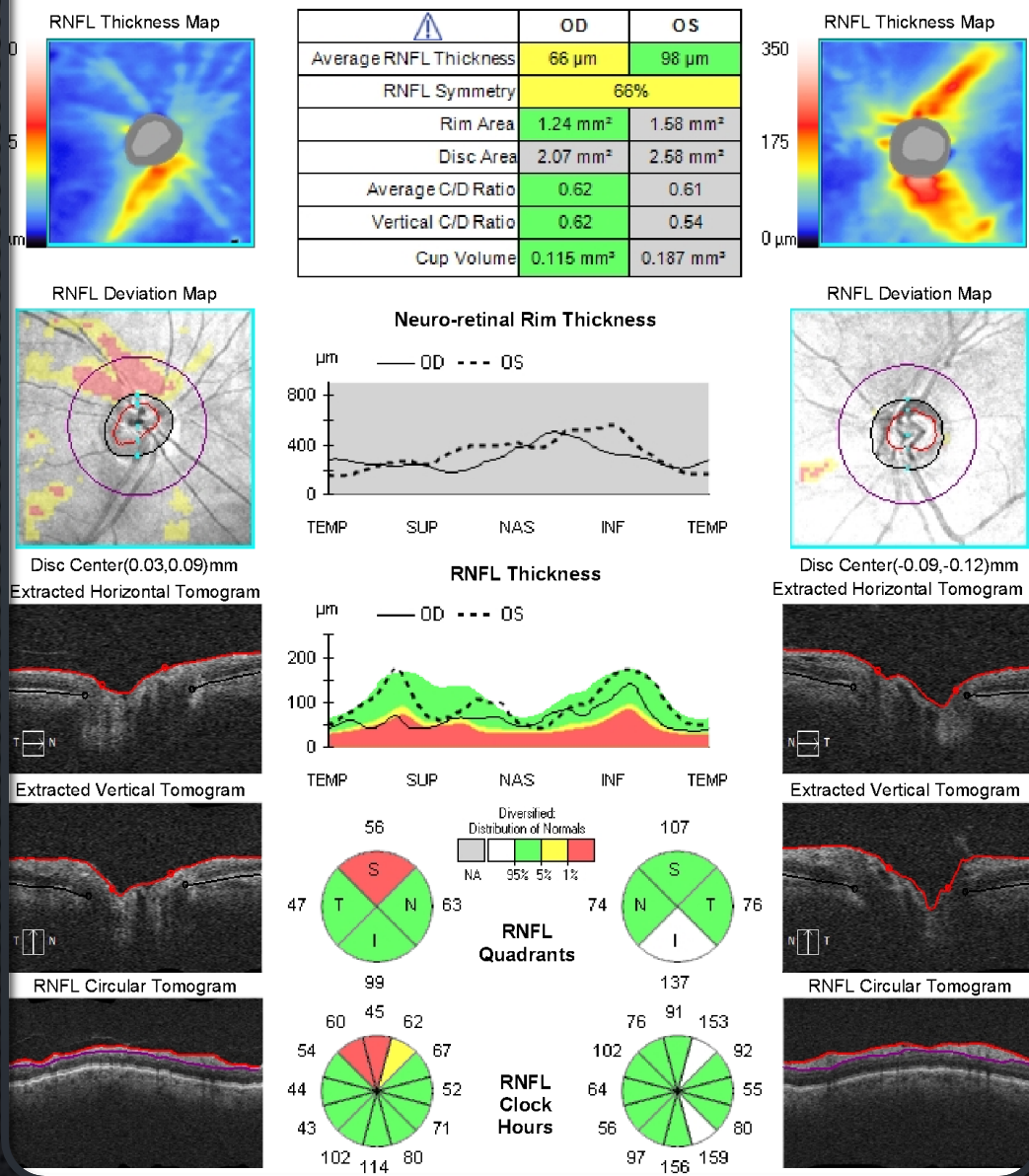
F/U 4-6 MONTHS GOAL IOP LOW/MID-TEENS WITH ANNUAL  
HVF AND RNFL (STAGGERED)

## CASE 3

- GLAUCOMA REFERRAL FOR PROGRESSING VF OD WITH NORMAL MRI
- 78 YO MALE ACUTE DROP VA OD, UNDERWENT NEUROLOGICAL WORKUP/IMAGING – NL
- FH: NEG, NO ALLERGIES, NO VASCULOPATHIC RISK FACTORS
- CCT: 691/637, IOP 13/11 (NO GTTS)
- ANGLE: 10 CLOCK HOURS PAS, L. GRADE 4, NO PAS
- HX OF CE/IOL OU, DSEK (PBK) OD, STRABISMUS SURGERY







# CASE 3

- CORRECT AGE, MALE
- RELIABLE, GOOD SIGNAL STRENGTH
- NO ARTIFACTS
- FINDINGS: LARGE DISK
- OD: SUPERIOR THINNING
- OS: WNL

## CASE 3: ASSESSMENT AND PLAN

Called a friend

Confirmed not glaucoma

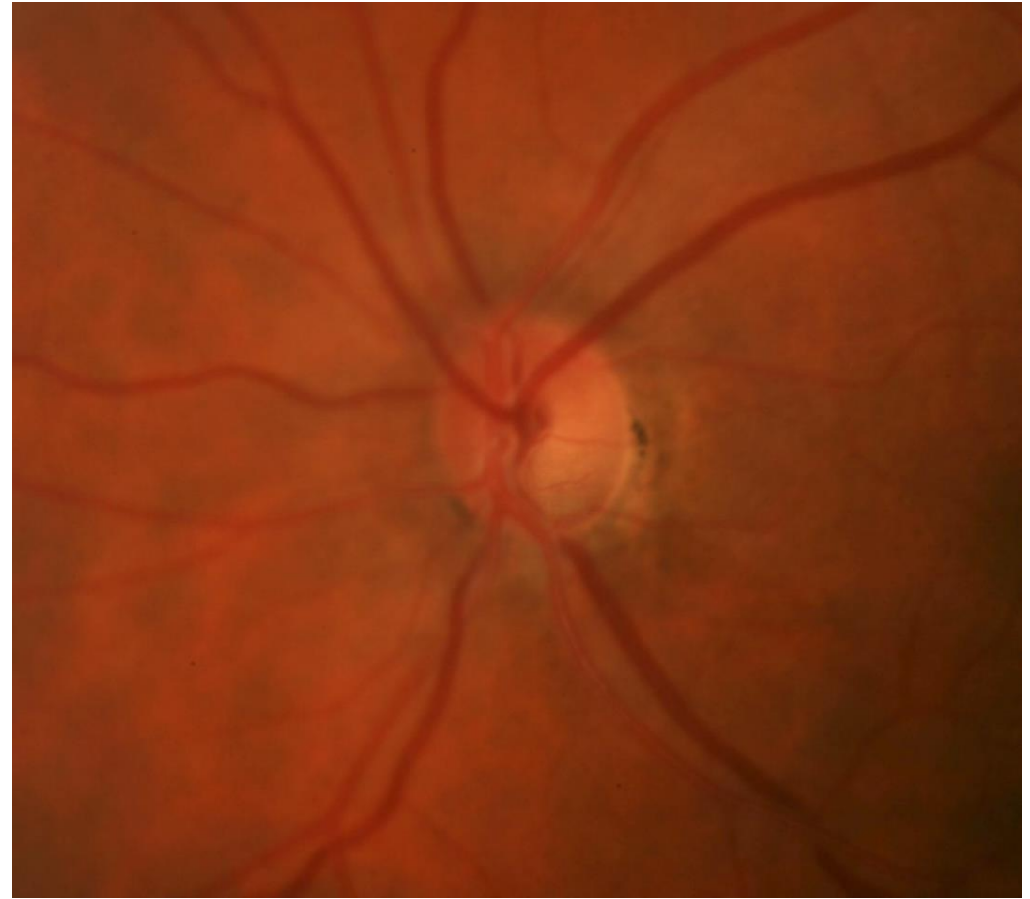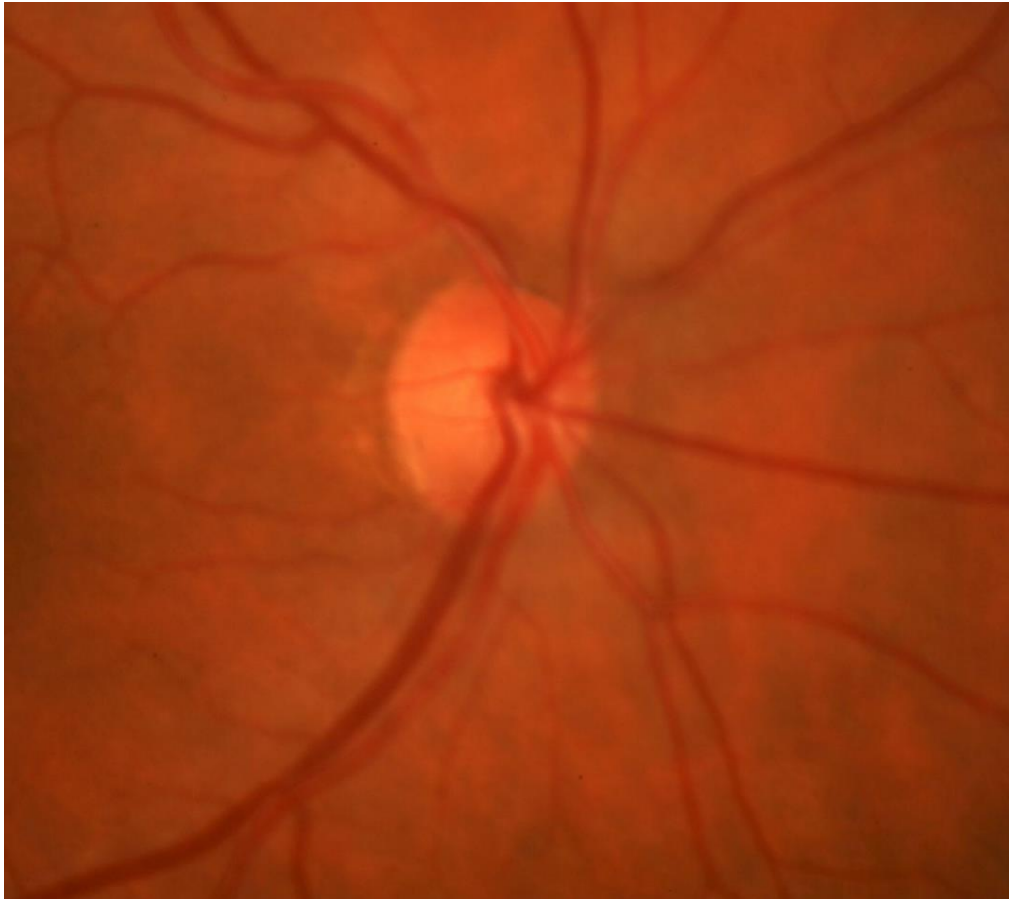
Appears more consistent with optic atrophy

Return to neuro-ophthalmology

Recommend repeating VF OD

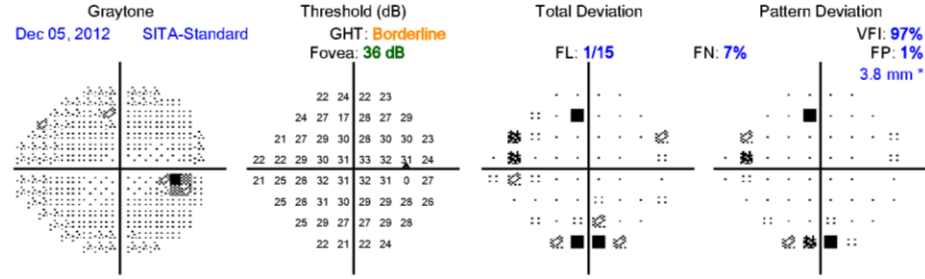
## CASE 4

- ESTABLISHED PATIENT WITH CHRONIC ANGLE CLOSURE GLAUCOMA
- 69 YO FEMALE, HIGH HYPEROPIA +6.75 OD, + 5.25 OS
- CHRONIC ANGLE CLOSURE S/P LPI OU
- FH: MOTHER, UNKNOWN TMAX, CCT 599, 589
- HX OF SLT – NO EFFECT, ALLERGIES: TRUSOPT AND + ASTHMA
- LAST GONIO (POST LI) GRADE 3, 3+ PTM SPECKLED, NO PAS
- MEDS: LATANOPROST 1/1, TRUSOPT 3/3, BRIMONIDINE 3/3, PILOCARPINE 2% 0/3
- LAST IOP 20 OD, 19 OS

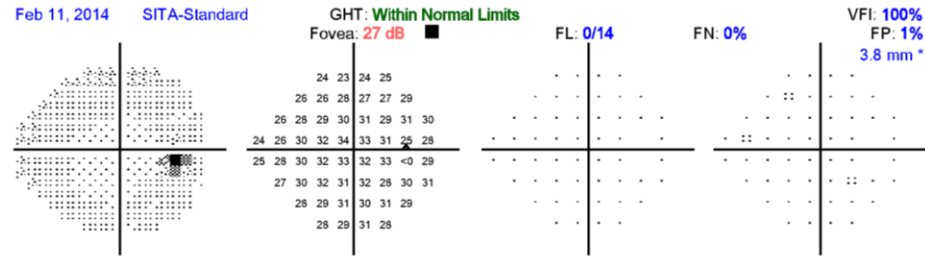


# OD Overview

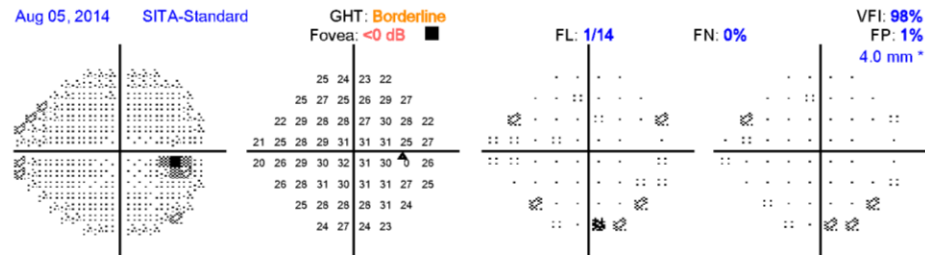
## Central 24-2 Threshold Test



MD: -2.60 dB P < 2% PSD: 2.70 dB P < 2%



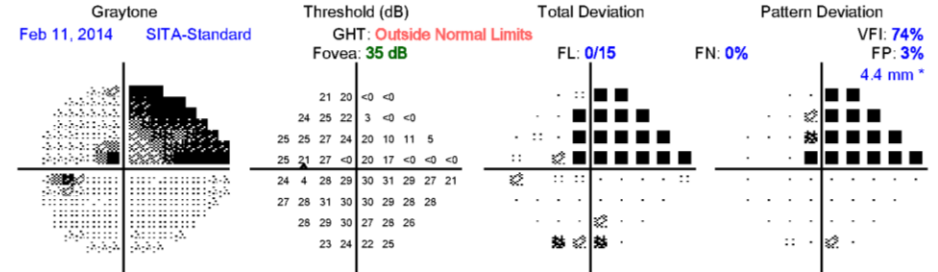
MD: -0.32 dB PSD: 1.36 dB



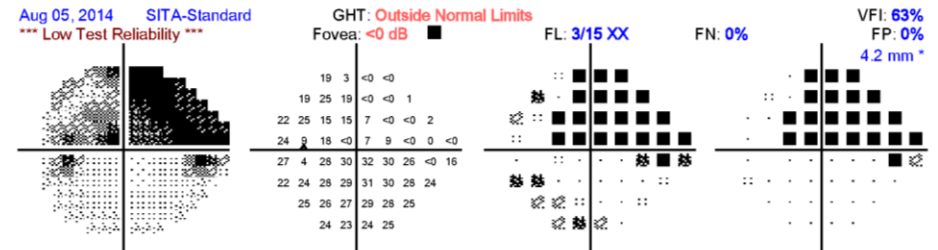
MD: -2.19 dB P < 5% PSD: 1.89 dB P < 10%

# OS Overview


## Central 24-2 Threshold Test



MD: -8.80 dB P < 0.5% PSD: 11.09 dB P < 0.5%



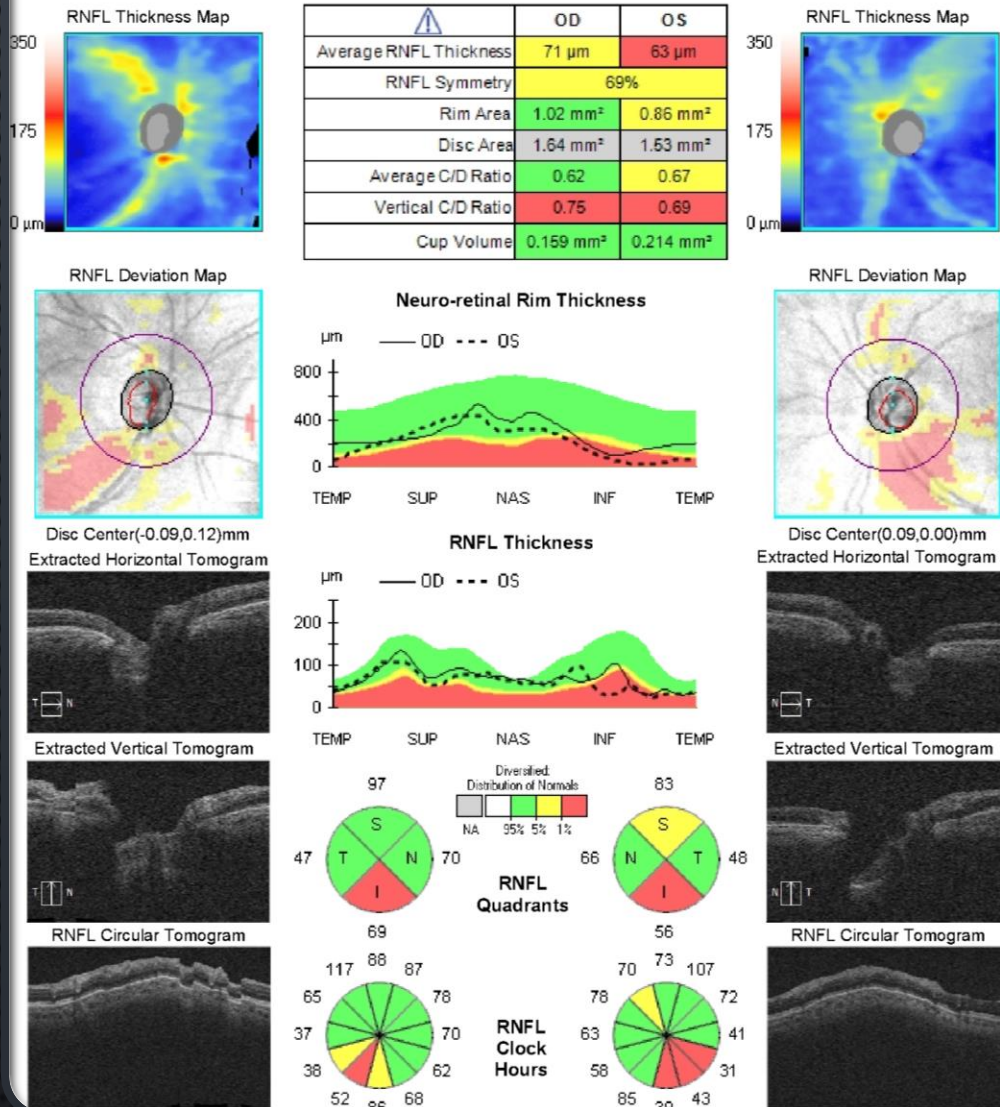
MD: -12.10 dB P < 0.5% PSD: 12.67 dB P < 0.5%



MD: -13.01 dB P < 0.5% PSD: 12.27 dB P < 0.5%

Sender: Female Serial Number: 5000-2634 5000-2634  
 Technician: Operator, Cirrus Signal Strength: 6/10 4/10

# ONH and RNFL OU Analysis: Optic Disc Cube 200x200 OD OS

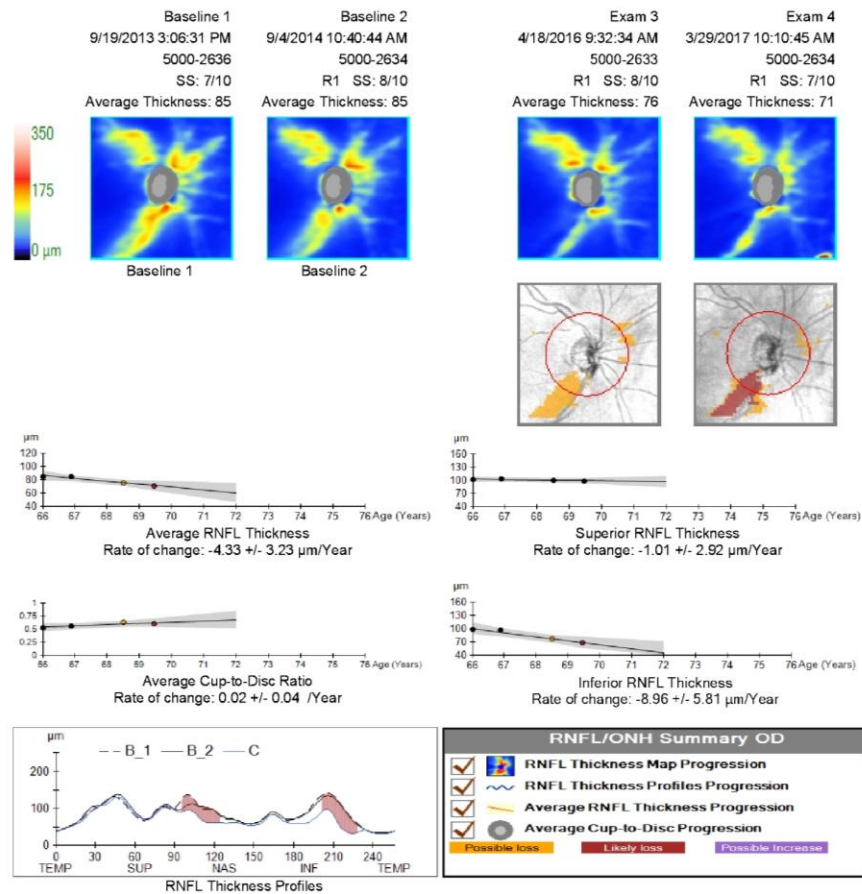


## CASE 4

- CORRECT AGE, FEMALE
- RELIABLE, GOOD SIGNAL STRENGTH OD
- LOW OS, IMAGE CAPTURE RELIABLE
- NO ARTIFACTS
- FINDINGS: AVERAGE DISC
- OD: INFERIOR THINNING
- OS: INFERIOR THINNING, SUPERIOR BORDERLINE

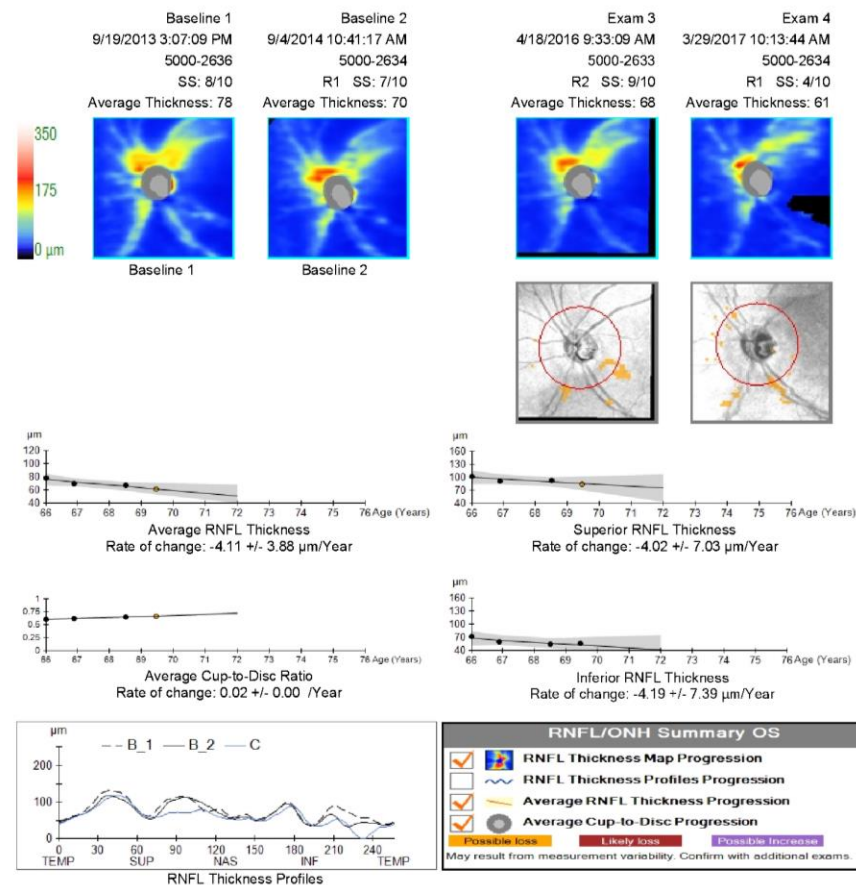
7/10

OD ●	○ OS
------	------



4/10

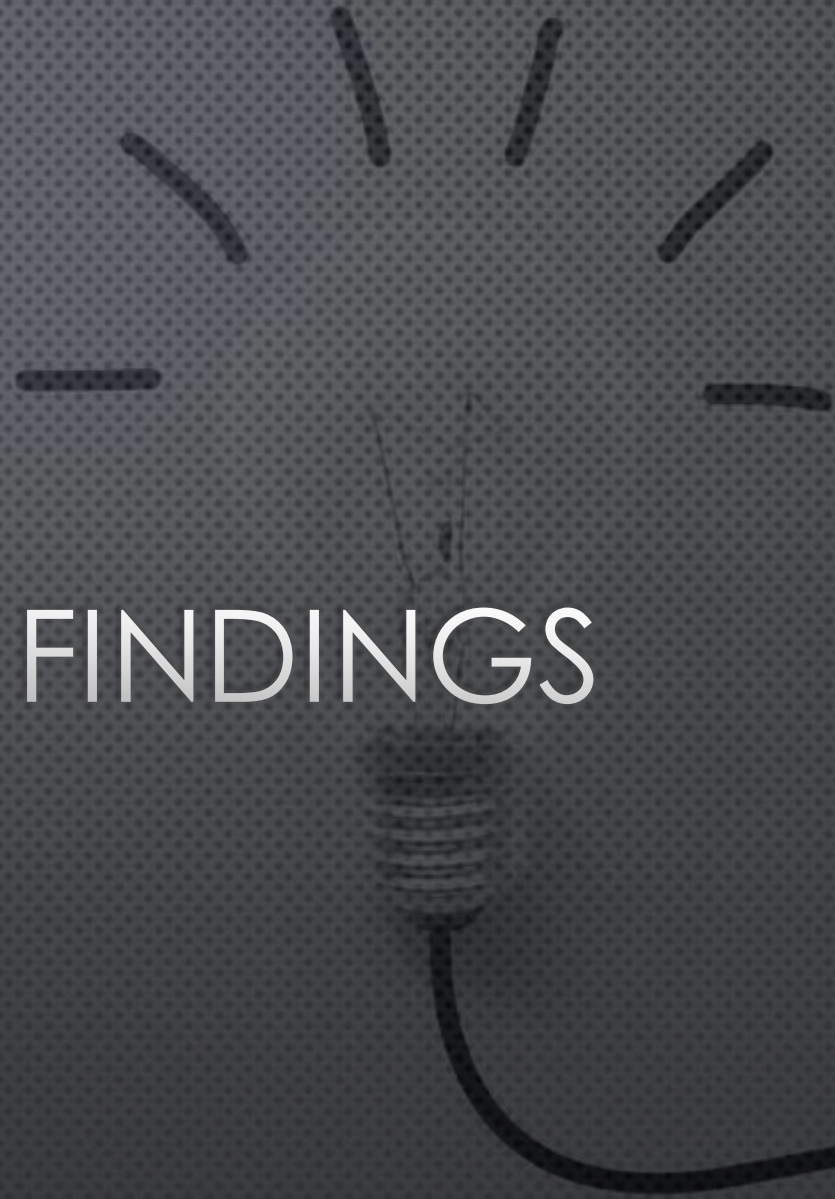OD ☐ OS ☒

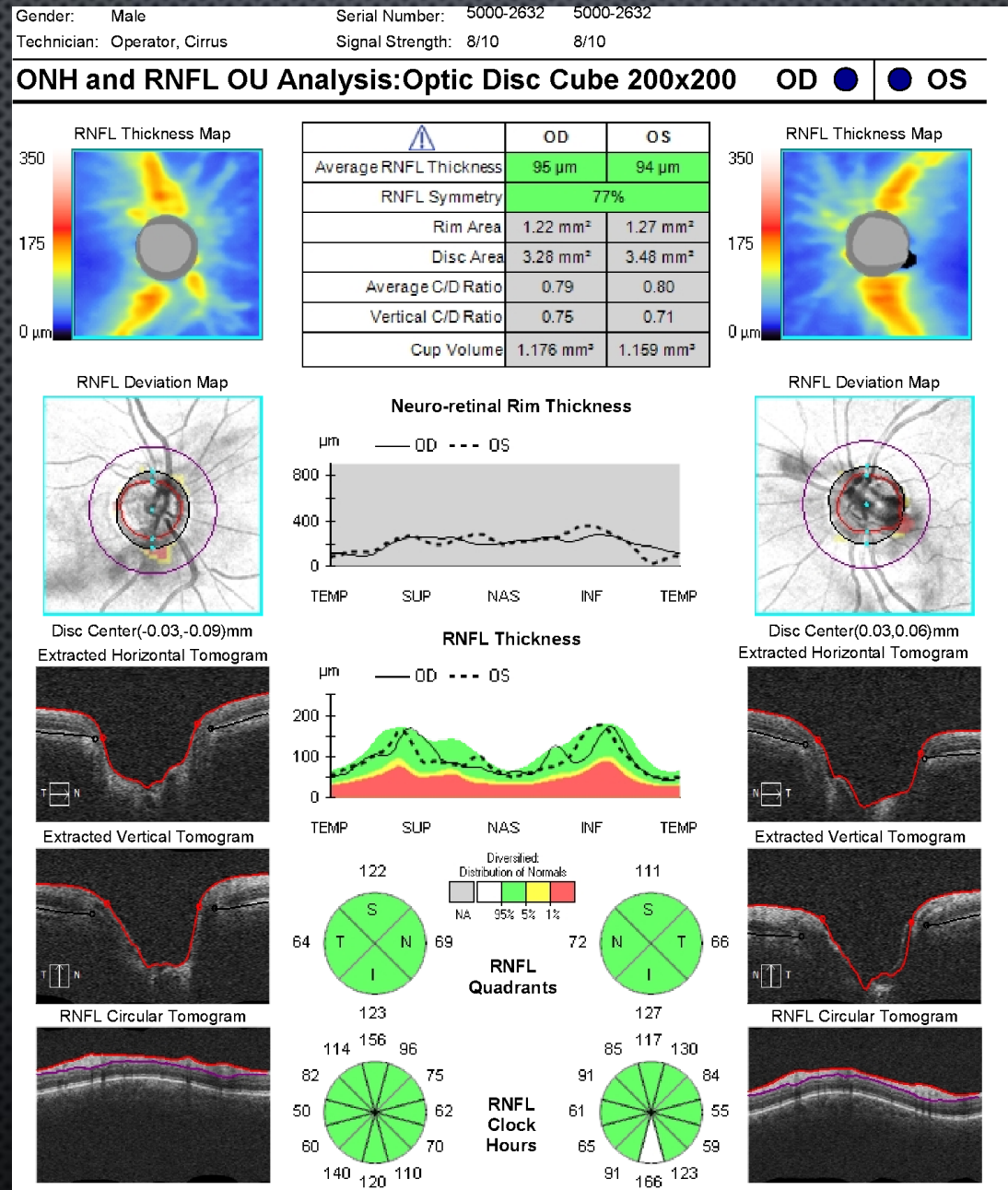


# CASE 4: ASSESSMENT AND PLAN

- CACG MILD STAGE OD, MODERATE STAGE OS
- IOP ABOVE GOAL OU
- OD: ADD PILOCARPINE
- OS: RECOMMEND SURGERY – TRAB VS TUBE VS. MIGS
- UNDERWENT CE/IOL w/ ISTENT OS
- 2 MONTHS LATER UCVA OS 20/20 MRX -0.5 SPHERE, IOP 19->13 ON 1 LESS MEDICATION OS

# OTHER RNFL FINDINGS





Reliable?

Overall nerve quality?

Overall size nerve

Asymmetry?

Overall thickness

Localized atrophy?

Assessment

Reliable? YES

Overall nerve quality?  
GOOD

Overall size nerve  
VERY LARGE

Asymmetry? NONE

Overall thickness: NL

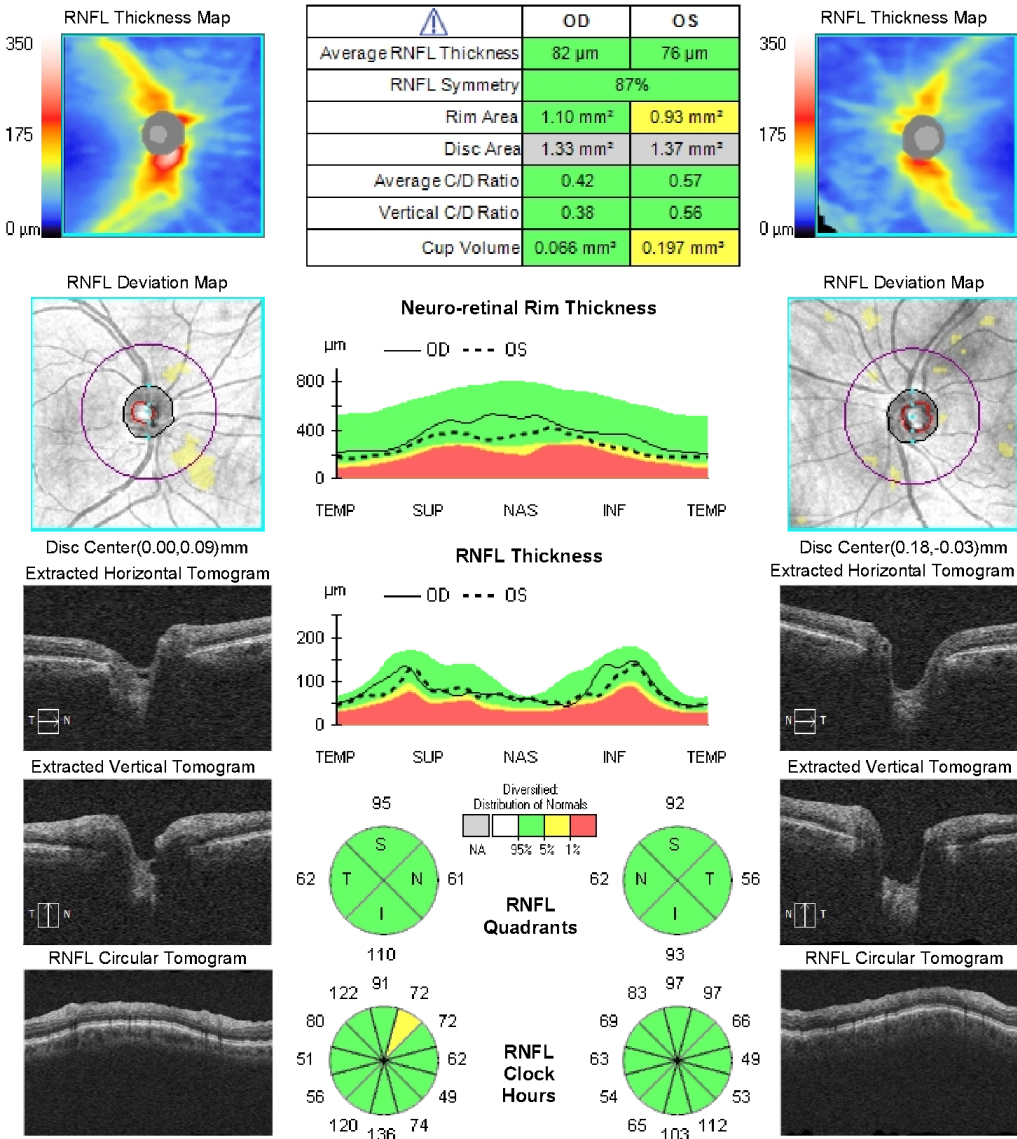
Localized atrophy? None

Assessment:  
Very large disk  
Physiologic cupping

ONH and RNFL OU Analysis:Optic Disc Cube 200x200

OD

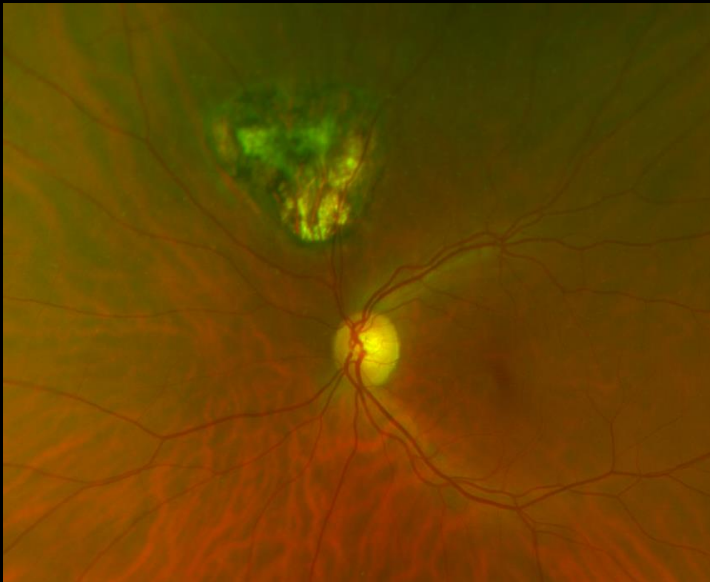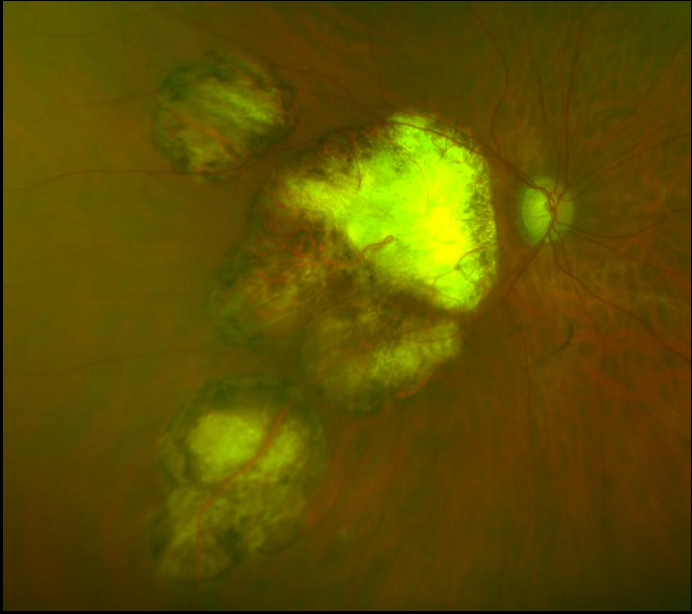
OS



NORMAL  
BUT WITH  
ASYMMETRY

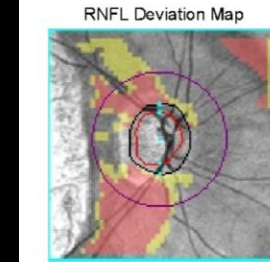
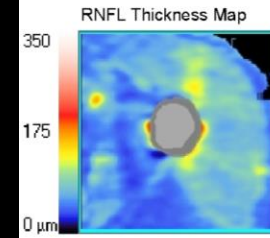
# OTHER ARTIFACTS

- OCULAR SURFACE
- CATARACT
- ANY MEDIA OPACITY
- PVD
- OTHER RETINAL CONDITIONS

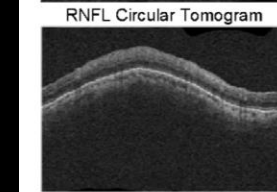
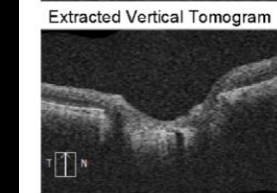
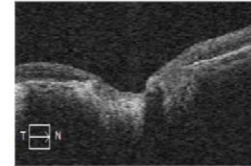


Gender: Female Serial Number: 5000-2634 5000-2634  
 Technician: Operator, Cirrus Signal Strength: 7/10 6/10

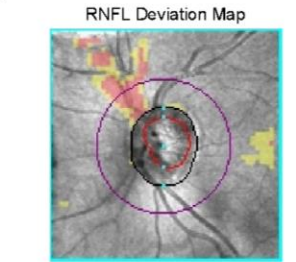
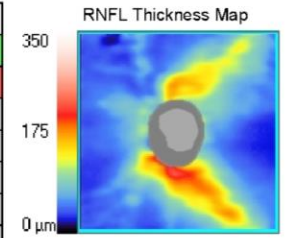
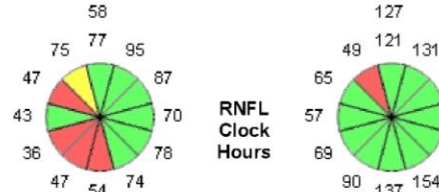
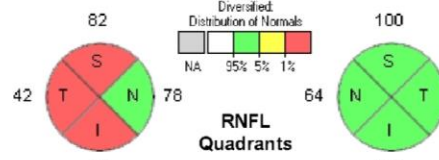
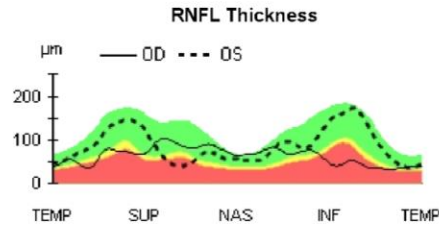
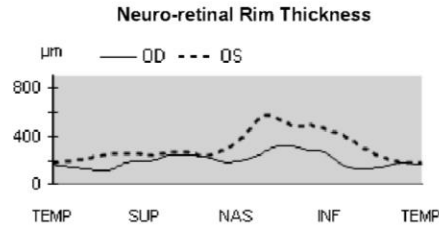
# ONH and RNFL OU Analysis: Optic Disc Cube 200x200 OD OS



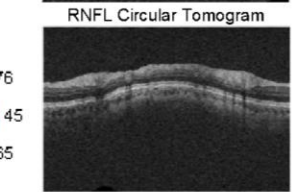
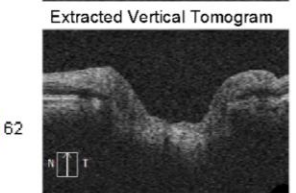
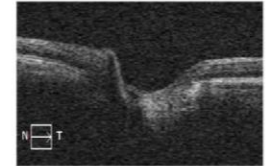
Disc Center: (-0.15, 0.18) mm  
 Extracted Horizontal Tomogram



	OD	OS
Average RNFL Thickness	65 $\mu$ m	88 $\mu$ m
RNFL Symmetry	-14%	
Rim Area	0.97 mm <sup>2</sup>	1.58 mm <sup>2</sup>
Disc Area	2.33 mm <sup>2</sup>	2.78 mm <sup>2</sup>
Average C/D Ratio	0.75	0.65
Vertical C/D Ratio	0.76	0.63
Cup Volume	0.333 mm <sup>3</sup>	0.319 mm <sup>3</sup>



Disc Center: (-0.09, 0.00) mm  
 Extracted Horizontal Tomogram

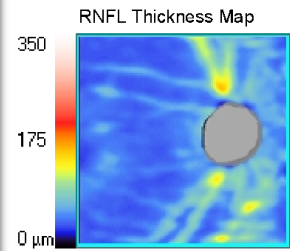


Gender: Male  
Technician: Operator, Cirrus

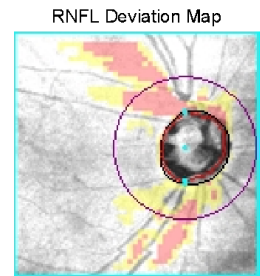
Serial Number: 5000-2633  
Signal Strength: 7/10

# ONH and RNFL OU Analysis: Optic Disc Cube 200x200

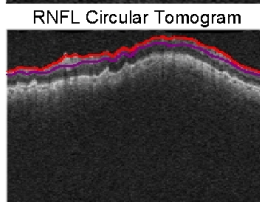
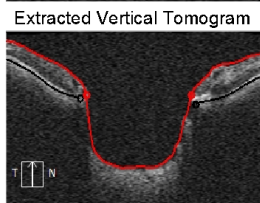
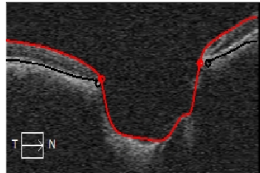
OD ● ○ OS



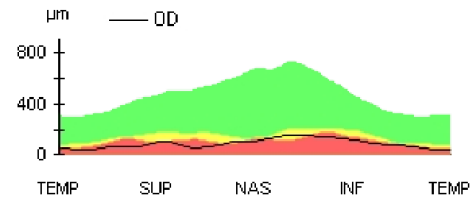
	OD	OS
Average RNFL Thickness	62 $\mu\text{m}$	X
RNFL Symmetry	X	
Rim Area	0.49 $\text{mm}^2$	X
Disc Area	2.41 $\text{mm}^2$	X
Average C/D Ratio	0.90	X
Vertical C/D Ratio	0.87	X
Cup Volume	1.440 $\text{mm}^3$	X



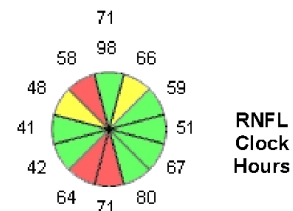
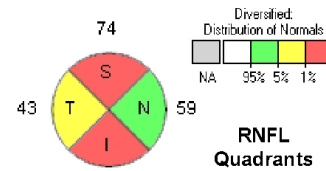
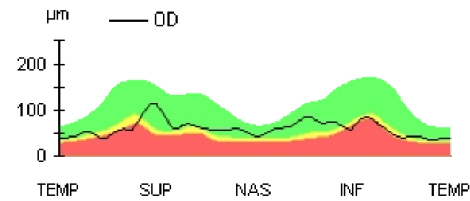
Disc Center(1.14,0.19)mm  
Extracted Horizontal Tomogram



## Neuro-retinal Rim Thickness



## RNFL Thickness



Gender: Male  
Patient ID: 8358729

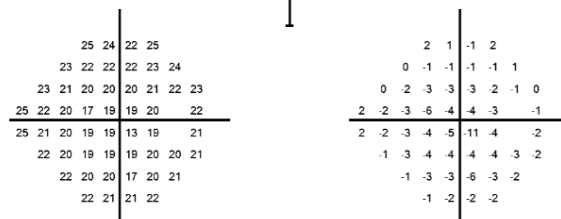
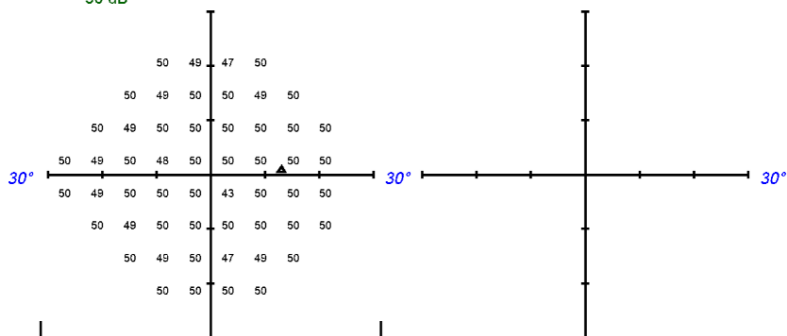
## OD Single Field Analysis

## Central 24-2 Threshold Test

Fixation Monitor: Gaze/Blind Spot  
Fixation Target: Central  
Fixation Losses: 15/15 XX  
False POS Errors: 73% XX  
False NEG Errors: 3%  
Test Duration: 06:41  
Fovea: 50 dB

Stimulus: III, White  
Background: 31.5 asb  
Strategy: SITA-Standard  
Pupil Diameter: 4.9 mm \*  
Visual Acuity: 4.9 mm \*  
Rx: +5.00 DS

Date: Sep 21, 2016  
Time: 1:48 PM  
Age: 85



Total Deviation

Pattern Deviation

GHT: Abnormally High Sensitivity

VFI: 76%

MD: 20.41 dB  
PSD: 2.25 dB P < 5%

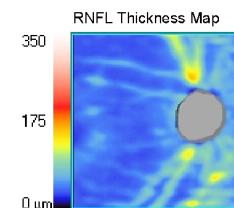
\*\*\* Excessive High False Positives \*\*\*

:: P < 5%  
:: P < 2%  
:: P < 1%  
■ P < 0.5%

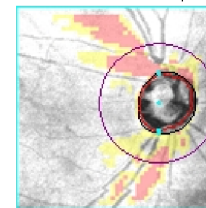
Gender: Male  
Technician: Operator, Cirrus  
Serial Number: 0000-2033  
Signal Strength: 7/10

## ONH and RNFL OU Analysis: Optic Disc Cube 200x200

OD OS

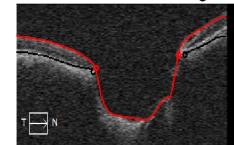


RNFL Deviation Map

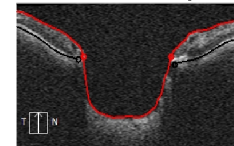


Disc Center(1.14,0.19)mm

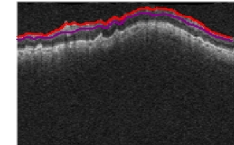
Extracted Horizontal Tomogram



Extracted Vertical Tomogram

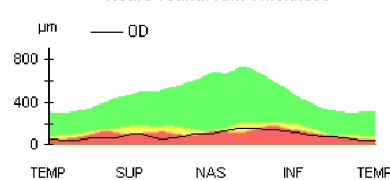


RNFL Circular Tomogram

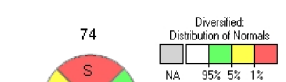
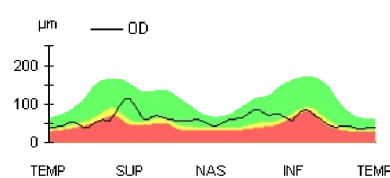


	OD	OS
Average RNFL Thickness	62 µm	X
RNFL Symmetry	X	
Rim Area	0.49 mm²	X
Disc Area	2.41 mm²	X
Average C/D Ratio	0.90	X
Vertical C/D Ratio	0.87	X
Cup Volume	1.440 mm³	X

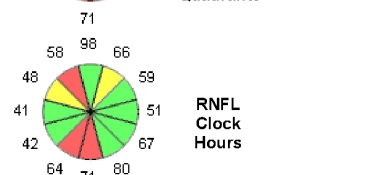
Neuro-retinal Rim Thickness

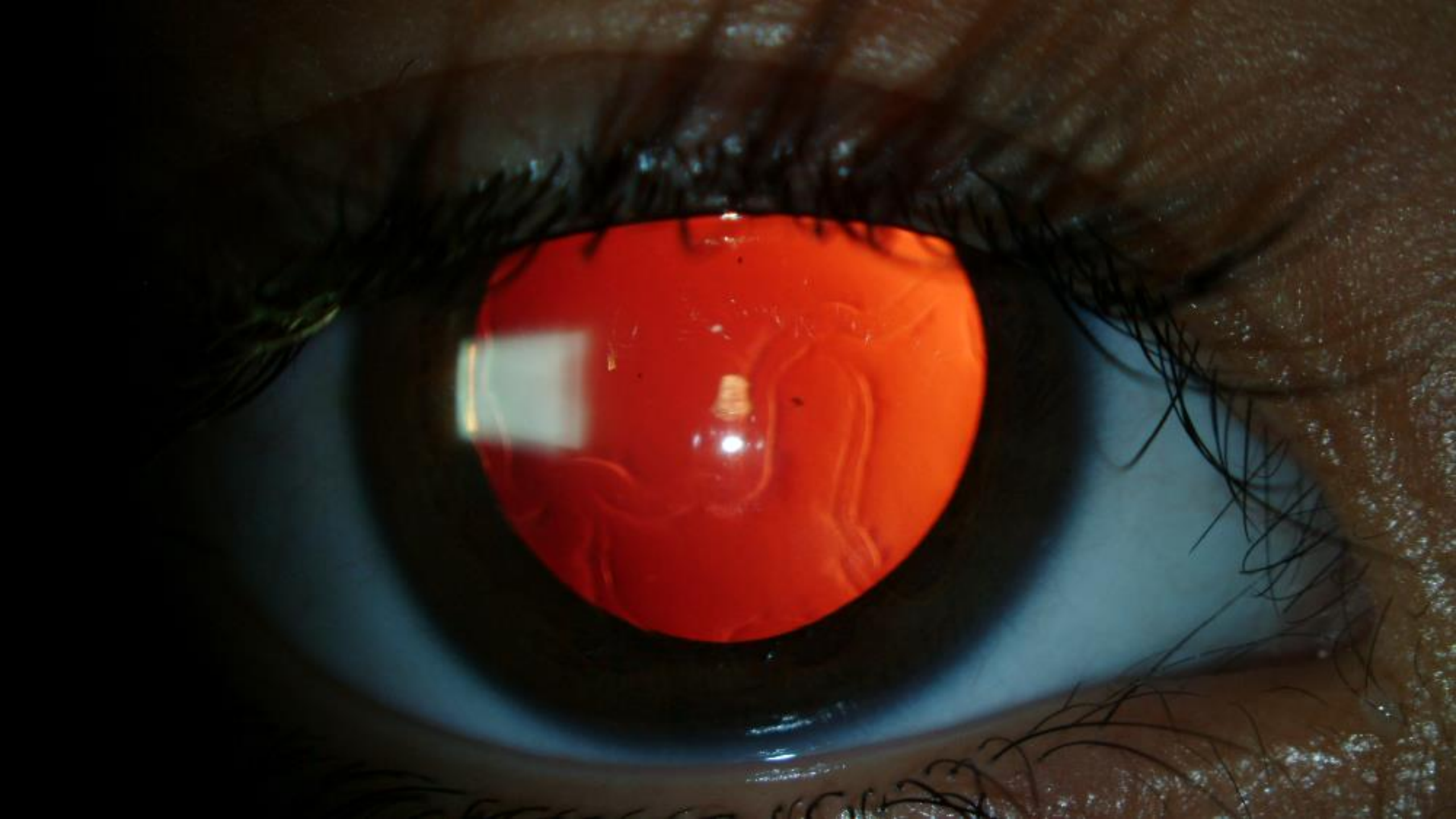


RNFL Thickness



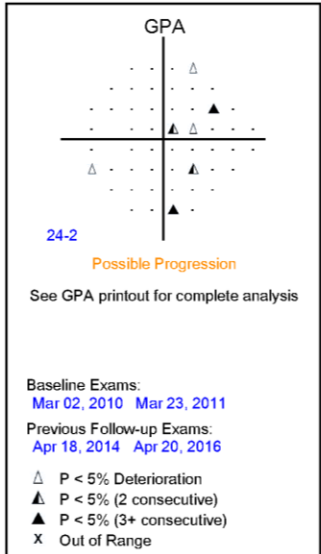
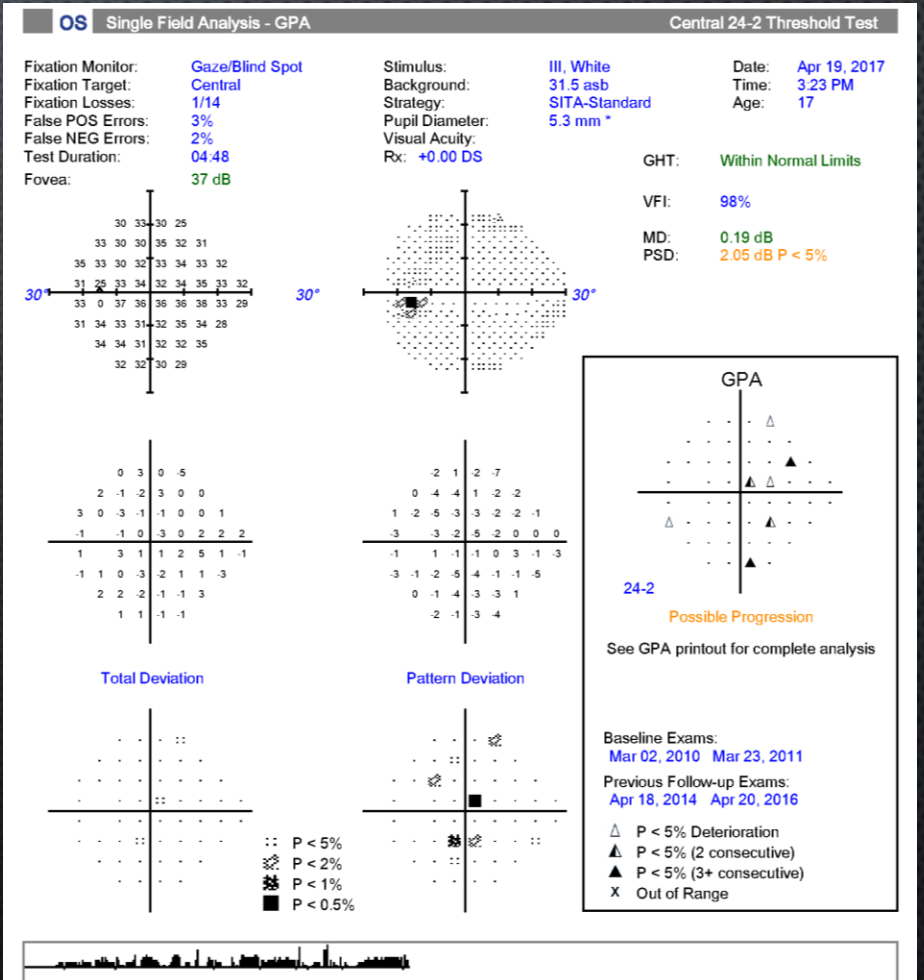
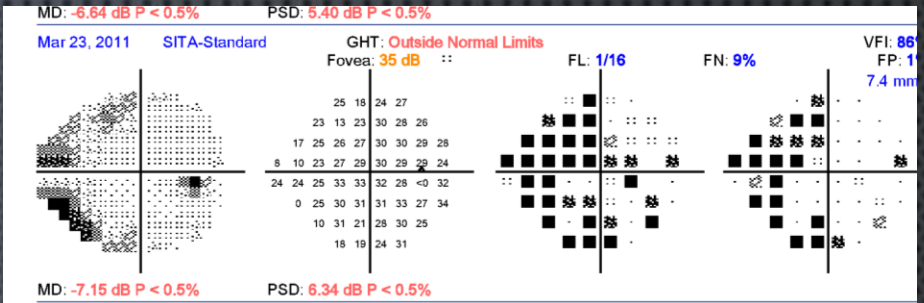
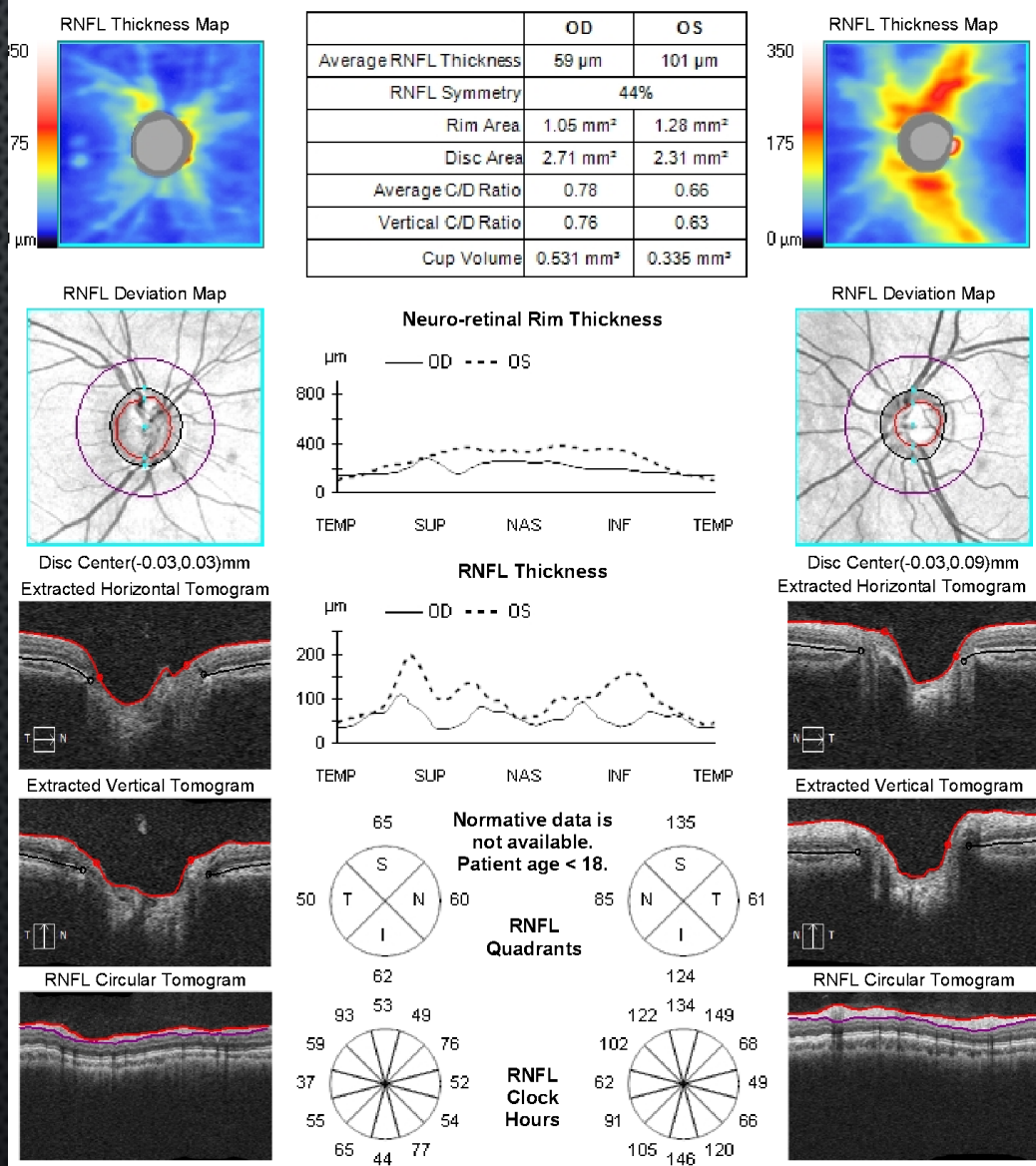
RNFL Clock Hours





OB: 12/15/1999      Exam Time: 3:34 PM      3:33 PM  
Gender: Male      Serial Number: 5000-2633      5000-2633  
Technician: Operator, Cirrus      Signal Strength: 9/10      10/10

**DNH and RNFL OU Analysis: Optic Disc Cube 200x200**      OD ●      ● OS

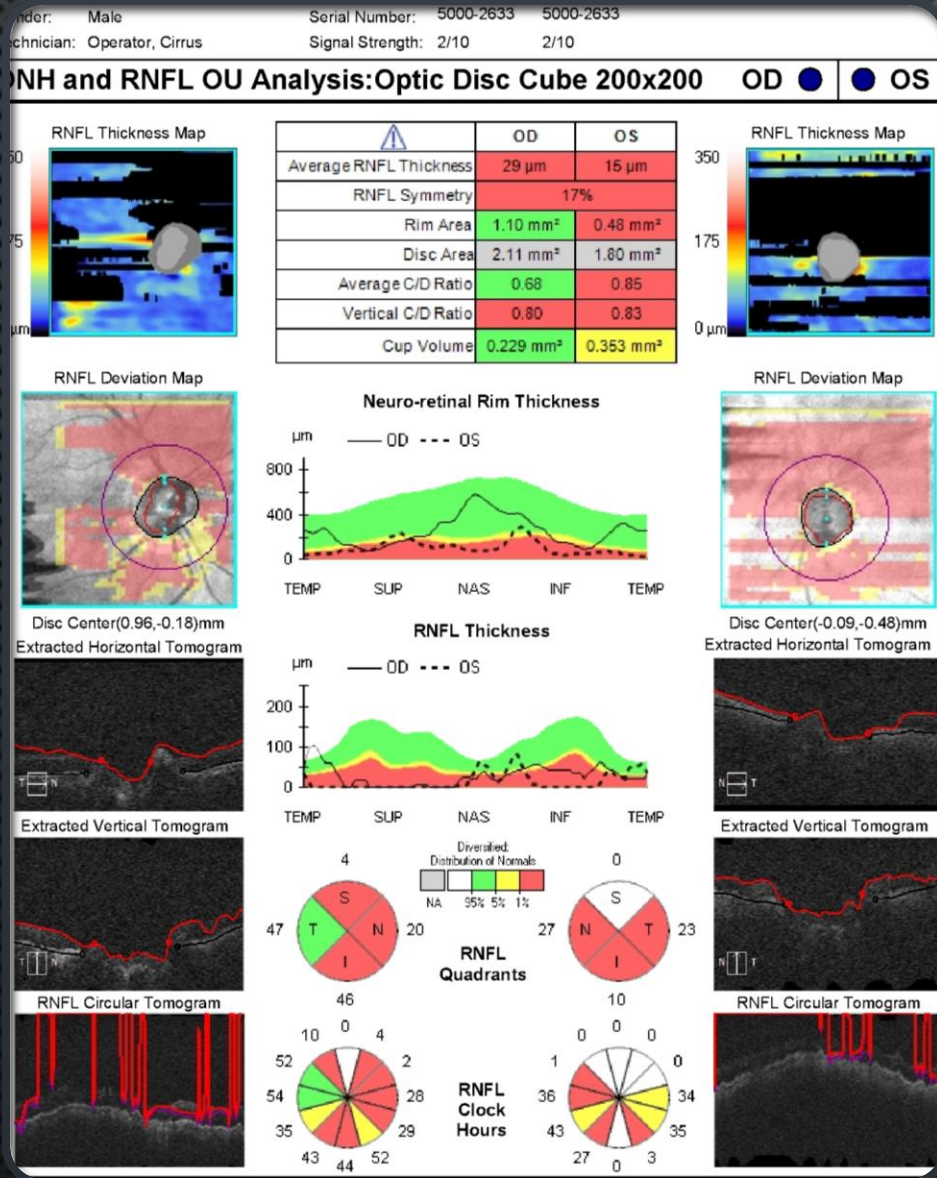


24-2  
Possible Progression  
See GPA printout for complete analysis

Baseline Exams:  
Mar 02, 2010      Mar 23, 2011  
Previous Follow-up Exams:  
Apr 18, 2014      Apr 20, 2016

△ P < 5% Deterioration  
▲ P < 5% (2 consecutive)  
▲ P < 5% (3+ consecutive)  
X Out of Range






SEVERE DRY  
EYES

DON'T JUST  
LOOK AT THE  
NUMBERS!

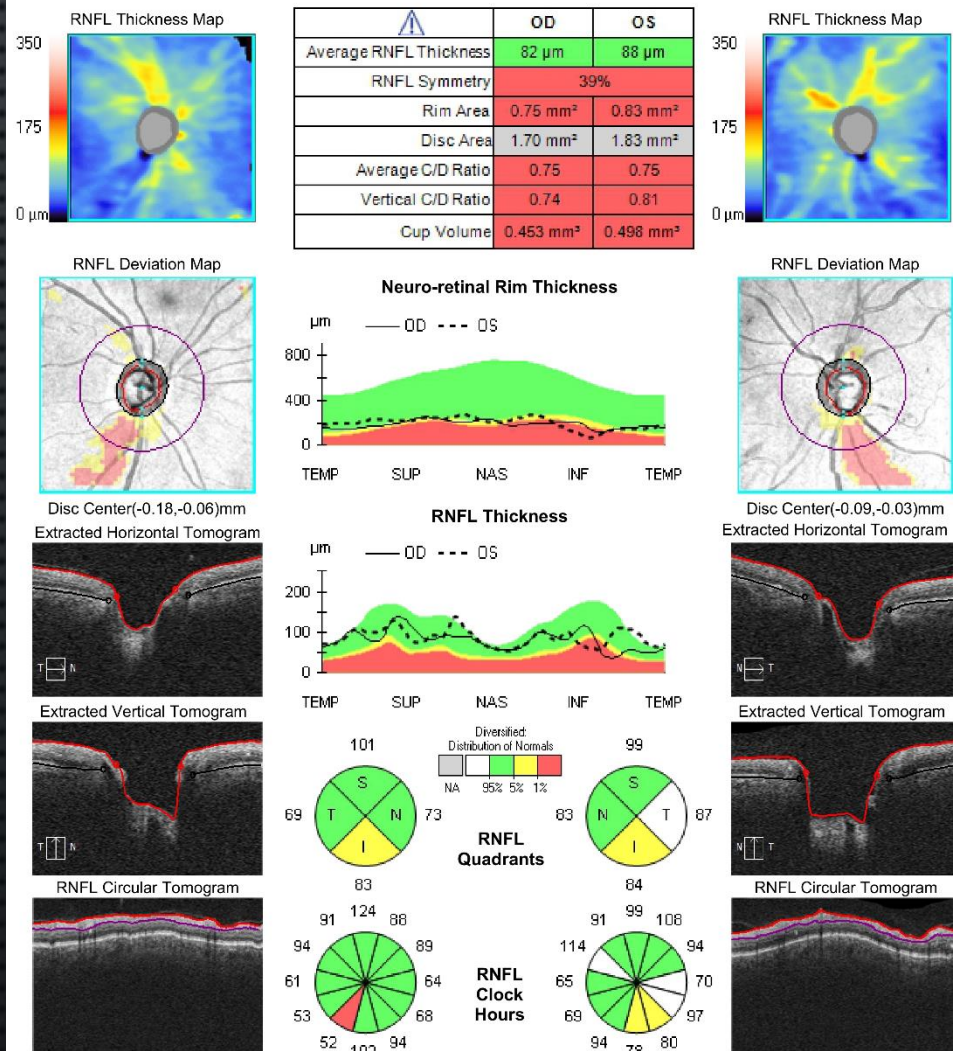
DOB:	5/13/1945	Exam Time:	2:47 PM	2:48 PM
Gender:	Female	Serial Number:	5000-2632	5000-2632
Technician:	Operator, Cirrus	Signal Strength:	10/10	8/10

**ONH and RNFL OU Analysis: Optic Disc Cube 200x200**    OD ●    ● OS

350	RNFL Thickness Map		OD	OS	350	RNFL Thickness Map
						
	Average RNFL Thickness		82 µm	88 µm		

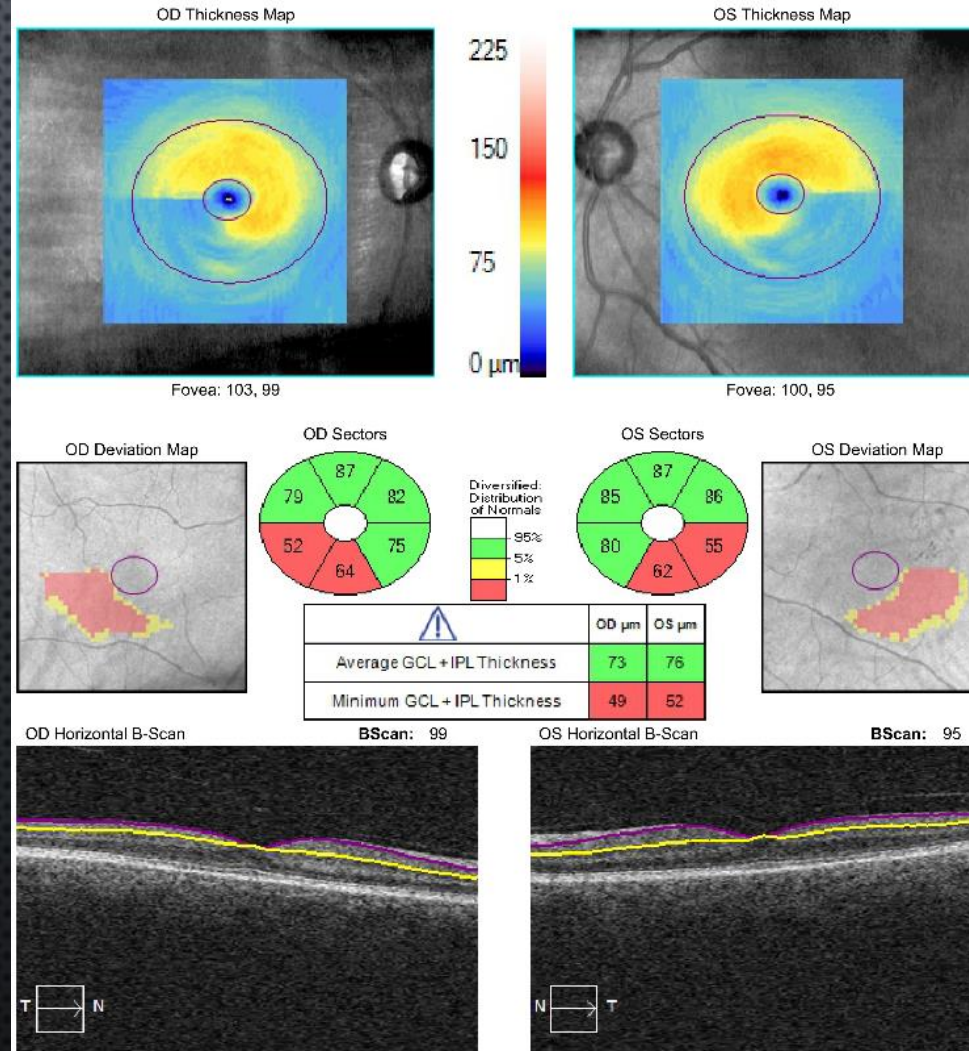
DOB: 5/13/1945 Exam Time: 2:47 PM 2:48 PM  
 Gender: Female Serial Number: 5000-2632 5000-2632  
 Technician: Operator, Cirrus Signal Strength: 10/10 8/10

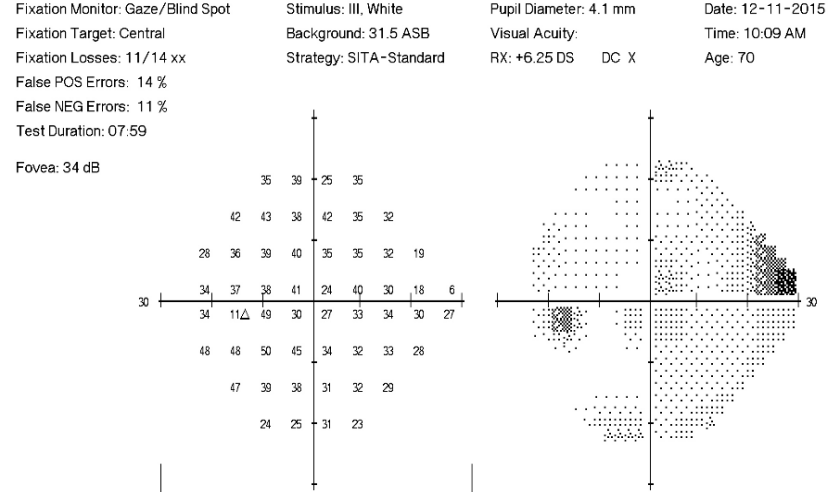
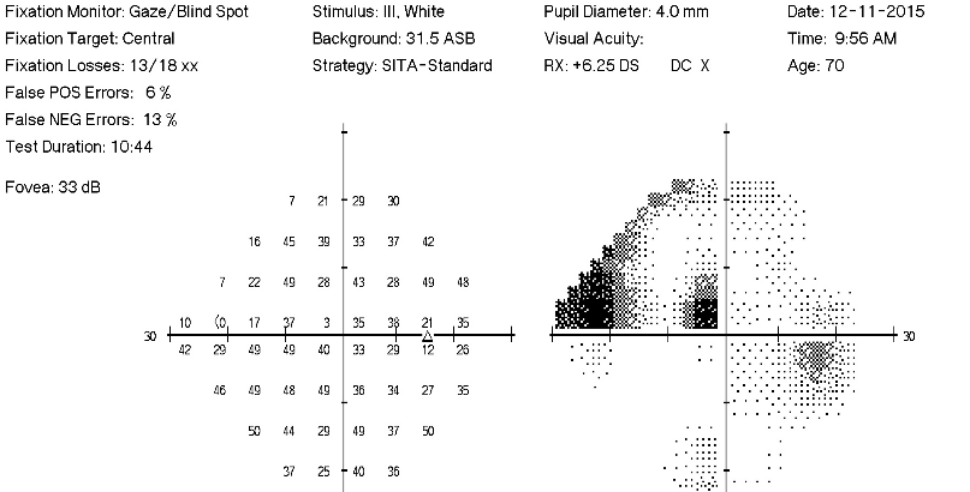
## ONH and RNFL OU Analysis: Optic Disc Cube 200x200 OD OS



DOB: 5/13/1945 Exam Time: 9:02 AM 9:03 AM  
 Gender: Female Serial Number: 5000-2636 5000-2636  
 Technician: Bonk, William Signal Strength: 9/10 8/10

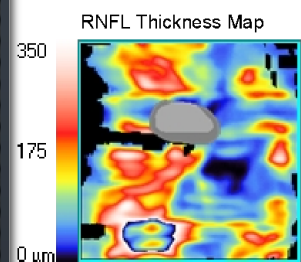
## Ganglion Cell OU Analysis: Macular Cube 200x200 OD OS



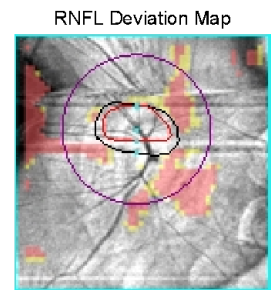
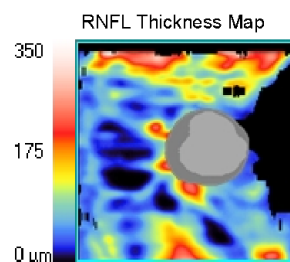


Gender: Female      Serial Number: 5000-2632      5000-2632  
 Technician: Operator, Cirrus      Signal Strength: 7/10      5/10

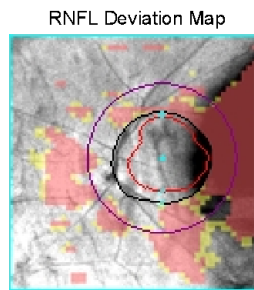
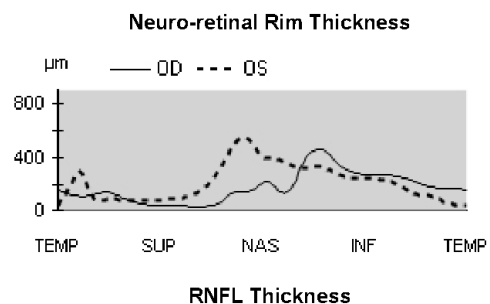
# ONH and RNFL OU Analysis: Optic Disc Cube 200x200      OD ●      ● OS



	OD	OS
Average RNFL Thickness	116 $\mu\text{m}$	53 $\mu\text{m}$
RNFL Symmetry	19%	
Rim Area	0.78 $\text{mm}^2$	1.34 $\text{mm}^2$
Disc Area	1.89 $\text{mm}^2$	3.90 $\text{mm}^2$
Average C/D Ratio	0.76	0.79
Vertical C/D Ratio	0.74	0.83
Cup Volume	0.200 $\text{mm}^3$	0.361 $\text{mm}^3$



Disc Center(-0.18,0.81)mm  
 Extracted Horizontal Tomogram



Disc Center(0.54,0.15)mm  
 Extracted Horizontal Tomogram

- POOR SIGNAL STRENGTH, CIRCLE NOT CENTERED ON NERVE
- WHAT TYPE OF EYES IS THIS TYPE OF SCAN SEEN IN?

DOB: 1/8/1946  
Gender: Female  
Technician: Operator, Cirrus

Exam Time: 1:29 PM  
Serial Number: 5000-2636  
Signal Strength: 7/10

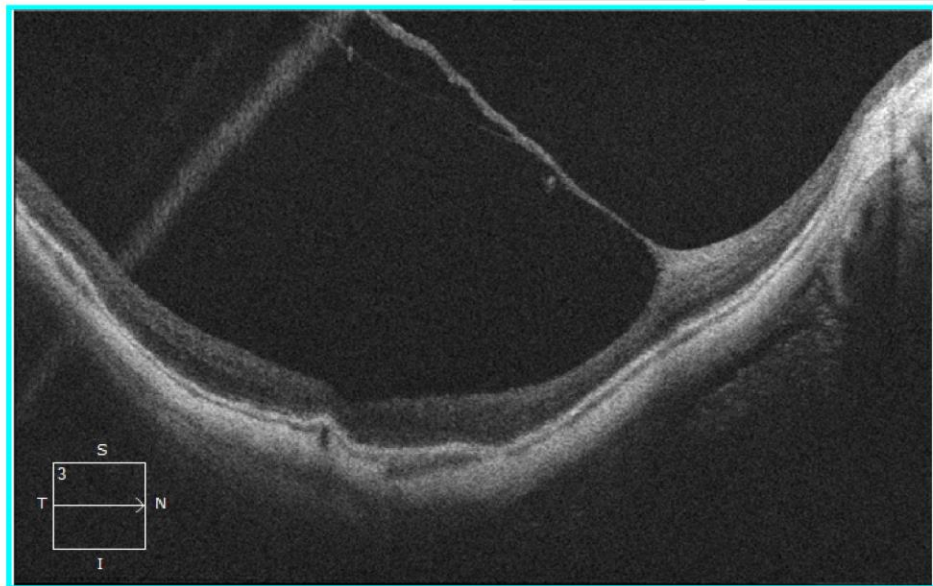
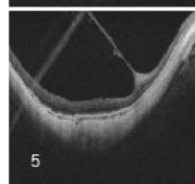
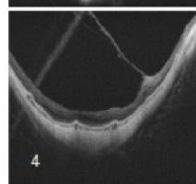
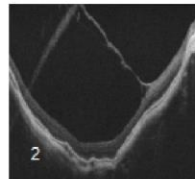
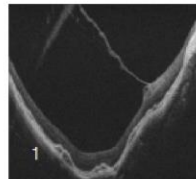
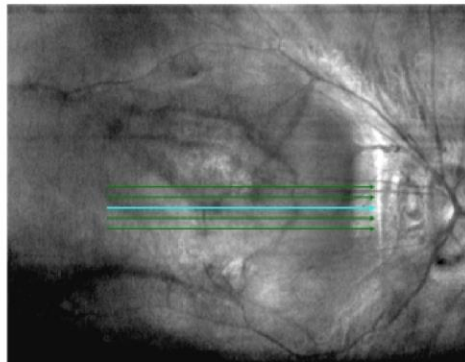
### High Definition Images: HD 5 Line Raster

OD ☒ OS ☐

Scan Angle: 0°

Spacing: 0.25 mm

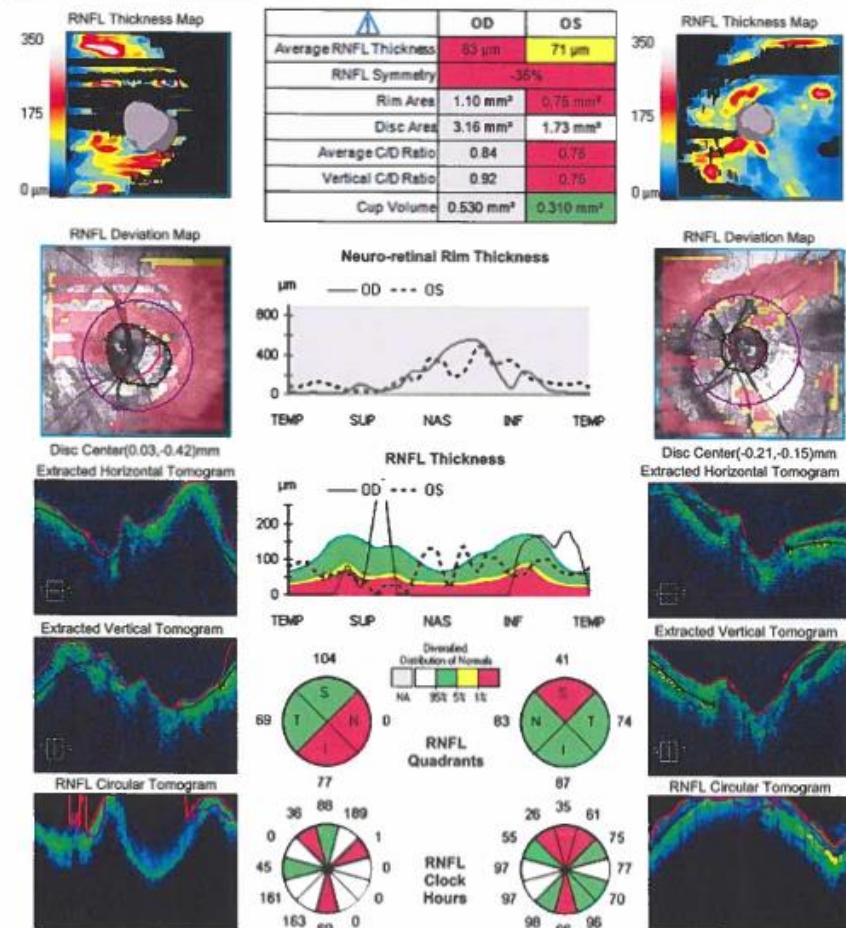
Length: 6 mm



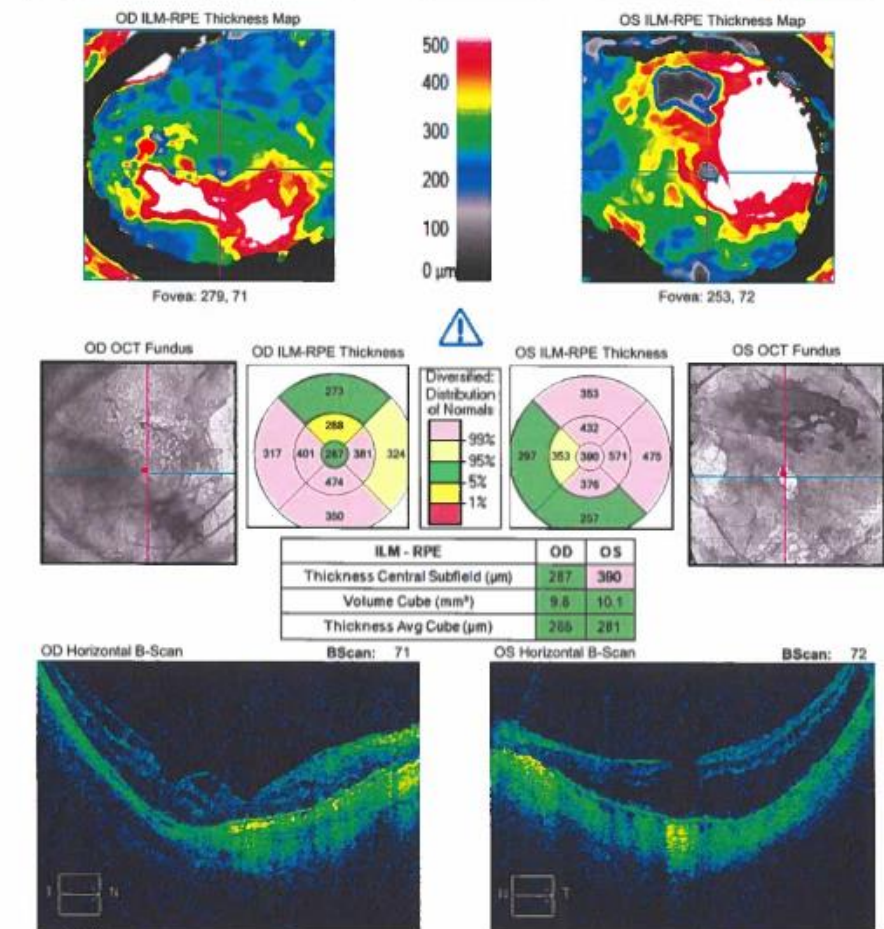
# MYOPIA

- VERY LONG AXIAL LENGTH WITH STAPHYLOMA

# ONH and RNFL OU Analysis: Optic Disc Cube 200x200 OD OS



# Macula Thickness OU: Macular Cube 512x128 OD OS


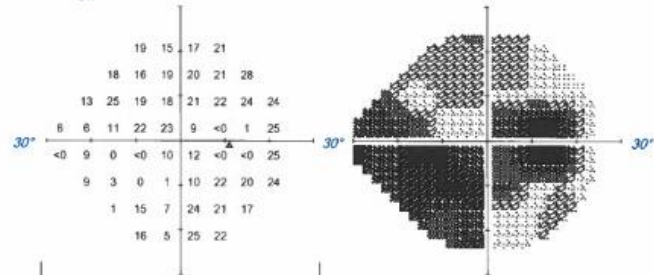


# OD Single Field Analysis Central 24-2 Threshold Test


Fixation Monitor: Blind Spot  
 Fixation Target: Central  
 Fixation Losses: 4/12 XX  
 False POS Errors: 0%  
 False NEG Errors: Off  
 Test Duration: 04:40  
 Fovea: Off

Stimulus: III, White  
 Background: 31.5 asb  
 Strategy: SITA Faster  
 Pupil Diameter:  
 Visual Acuity:  
 Rx: +4.50 DS +2.00 DC X 55

Date: May 26, 2021  
 Time: 2:30 PM  
 Age: 81



Total Deviation



Pattern Deviation

GHT: Outside Normal Limits

VFI: 51%  
 MD24-2: -15.57 dB P < 0.5%  
 PSD24-2: 10.16 dB P < 0.5%

\*\*\* Low Test Reliability \*\*\*

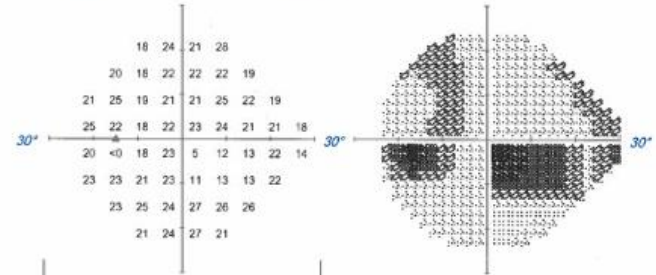
:: P < 5%  
 : P < 2%  
 . P < 1%  
 ■ P < 0.5%

# OS Single Field Analysis Central 24-2 Threshold Test


Fixation Monitor: Gaze/Blind Spot  
 Fixation Target: Central  
 Fixation Losses: 1/9  
 False POS Errors: 2%  
 False NEG Errors: Off  
 Test Duration: 02:47  
 Fovea: Off

Stimulus: III, White  
 Background: 31.5 asb  
 Strategy: SITA Faster  
 Pupil Diameter:  
 Visual Acuity:  
 Rx: +5.00 DS

Date: May 26, 2021  
 Time: 2:37 PM  
 Age: 81



Total Deviation



Pattern Deviation

GHT: Outside Normal Limits

VFI: 74%  
 MD24-2: -8.85 dB P < 0.5%  
 PSD24-2: 5.81 dB P < 0.5%

:: P < 5%  
 : P < 2%  
 . P < 1%  
 ■ P < 0.5%

# MYOPIA AND GLAUCOMA

- MYOPIC DEGENERATION CAN CAUSE THE OPTIC NERVE TO HAVE AN ABNORMAL APPEARANCE
- MYOPIC DEGENERATION CAN PRODUCE FIELD DEFECTS THAT MIMIC GLAUCOMA
- ASSESS THE INTRAOCULAR PRESSURE CLOSELY AND BE SUSPICIOUS OF NORMAL PRESSURES
- IF SEEMS LIKE A LOW-RISK GLAUCOMA SUSPECT- FOLLOW
- IN HIGHER-RISK SITUATIONS WHERE TREATMENT IS NECESSARY- LOWER-RISK TREATMENTS

# MY RNFL PROTOCOL

- IN ANY NEW PATIENT IF VF DOESN'T CORRELATE WITH OPTIC NERVE OR VF UNRELIABLE
- IF NOT AT FIRST VISIT THEN AT FOLLOW-UP
- STABLE PATIENTS: YEARLY VF, YEARLY RNFL SPACED 6 MONTHS APART
- UNSTABLE PATIENTS: RNFL, VF Q3-6 MONTHS TO ESTABLISH CURVE AND STATISTICAL PROGRESSION ANALYSIS
- REVIEW SCAN PRIOR TO PATIENT LEAVING CONSIDER REPEATING IF ARTIFACTS
- POOR UTILITY IN VERY ADVANCED GLAUCOMA DUE TO BOTTOM EFFECT, OR IN OTHER CONDITIONS THAT LEAD TO ARTIFACTS SUCH AS VERY HIGH MYOPIA, DENSE MEDIA OPACITY ETC
- RESET GPA AFTER SURGICAL INTERVENTION DONE

THANK YOU